

Topoisomerase I Protein Expression and Prognosis of Patients with Colorectal Cancer

Masayuki Ataka, Masahide Ikeguchi, Manabu Yamamoto, Masashi Inoue, Takashi Tanida, Shin-ichi Oka and Kuniyuki Katano

Division of Surgical Oncology, Department of Surgery, School of Medicine, Tottori University Faculty of Medicine, Yonago 683-8504 Japan

Topoisomerase I (Topo I) is known as a target for chemotherapy in advanced or recurrent colorectal cancer. In order to prolong the survival of patients with colorectal cancer or to prevent ineffective chemotherapy, we evaluated clinicopathological characteristics of Topo I protein in colorectal cancer. Also, we estimated whether Topo I protein expression of primary tumors could be a parameter for chemosensitivity of Topo I inhibitor in patients with cancer recurrence. Immunohistochemical detection of Topo I protein was performed in 104 surgically obtained specimens. Topo I protein was detected in 45 of 104 patients (43.2%). Topo I protein expression closely correlated with tumor progression, histopathological differentiation and poor prognosis of patients. Sixteen patients with recurrent cancer had been treated with Topo I inhibitor. Topo I inhibitor significantly prolonged the survival of 12 patients who had Topo I-positive primary tumors. Topo I protein expression in colorectal cancer may be a biological marker for chemosensitivity of tumors against Topo I inhibitors.

Key words: chemosensitivity; colorectal cancer; DNA topoisomerase I; immunohistochemistry; prognosis

DNA topoisomerase I (Topo I) belongs to the DNA topoisomerase multimember family, which is essential for DNA topology modulation. Topo I transiently cleaves one strand of DNA, allowing relaxation of the supercoiled DNA. This process is important in cell replication, translation, recombination and repair (Gupta et al., 1995). Through Western and Northern blotting, Topo I protein and mRNA level were found to be more abundant in several human tumors than in normal tissues (Husain et al., 1994; Rowinsky et al., 1994; van der Zee et al., 1994; Giaccone et al., 1995).

Topo I is also a target for anticancer drugs, camptothecin and its derivatives (O'Leary and Muggia, 1998). Topo I-inhibiting drugs interfere

with Topo I function by binding to Topo I at its active site, and prevent re-ligation of the DNA strand (Goldwasew et al., 1995). Camptothecin inhibits Topo I by forming stable Topo I–DNA cleavage complexes, and is specifically cytotoxic for S-phase cells (Hsiang et al., 1989). In vitro, tumor cells with a high level of Topo I protein respond better to Topo I inhibitors (Staley et al., 1999).

CPT-11, a derivative of camptothecin, has been used as one of the key drugs for treating colorectal cancer (Paradiso et al., 2004; Vallböhmer et al., 2006). In the last few years, it has been shown that when used in combination with 5-fluorouracil and leucovorin, both CPT-11 and oxaliplatin

treatments demonstrated significant improvement in the clinical outcome of patients with advanced colorectal cancer (Doillard et al., 2000; de Gramont et al., 2000). However, response rates for these chemotherapeutic regimens still remain about 40% to 50%. In the present study, we investigated the clinicopathological characteristics of colorectal tumors with Topo I protein expression. Also, we analyzed Topo I protein expression in primary tumors could be a biomarker of chemosensitivity for recurrent patients or not.

Materials and Methods

Tumor samples

We obtained tumors and non-cancerous normal mucosa from 104 patients who underwent colorectal resection between 1992 and 2001. Samples were collected immediately after surgical resection of specimens. The tissues were fixed in 10% buffered formalin and embedded in paraffin. Four micrometer histological sections were destined to specific immunohistochemical determinations.

Immunohistochemistry

After paraffin-embedded sections on the slides were dewaxed and rehydrated gradually with graded alcohols, antigen retrieval was performed by autoclaving in 10 mol citrate buffer for 30 min. Endogenous peroxidase activity was blocked by methanol and 0.3% hydrogen peroxide. Slides were then incubated with primary anti Topo I monoclonal antibody (Clone 1D6, 1:50 dilution, Novocastra Laboratories, Newcastle, United Kingdom) for 1 h at room temperature. After incubation, the specimens were washed twice with phosphate-buffered saline solution (pH 7.6) and processed with the streptavidin-biotin peroxidase method according to the manufacturer's recommendations. The slides were then incubated in diaminobenzidine tetrahydrochloride and hydrogen-

peroxide chromogen substrate for 10 min at room temperature, washed in running water for 2 to 3 min, counterstained in Mayer's haematoxylin. Normal tonsil tissue was used as a positive control. It is known that normal tonsil tissue is well stained by immunohistochemistry which uses Topo I antibody (Rasheed and Rubin, 2003).

Scoring system

Tumor cells expressing Topo I immunoreactivity were quantified by 2 independent observers who evaluated at least 1,000 neoplastic cells in consecutive areas of neoplastic tissues. If there was a Topo I-positive cell in the tumor, the sample was classified as "positive". If there were no Topo I-positive cells, the sample was classified as "negative" (Paradiso et al., 2004).

Patients

Clinicopathological findings of colorectal cancer were defined according to Dukes' classification (Dukes and Bussey, 1958). In all 104 patients, curative colorectal resection was performed between 1992 and 2001 at Tottori University Hospital. Patients agreed to the use of their tissues by informed consent. None of the patients received preoperative chemotherapy, and all were followed until December 2006. The types of cancer recurrence were established by computed tomography, performed at least twice a year.

Statistical analysis

The chi-square test was used to compare the differences between the 2 groups. The overall and disease-free survivals were estimated using Kaplan-Meier's method and compared using a 2-sided log rank test. Cox's proportional hazards regression model was used to estimate the predictive power of Topo I protein expression on clinical outcome. Two-sided tests were computed, and $P < 0.05$ was considered statistically significant.

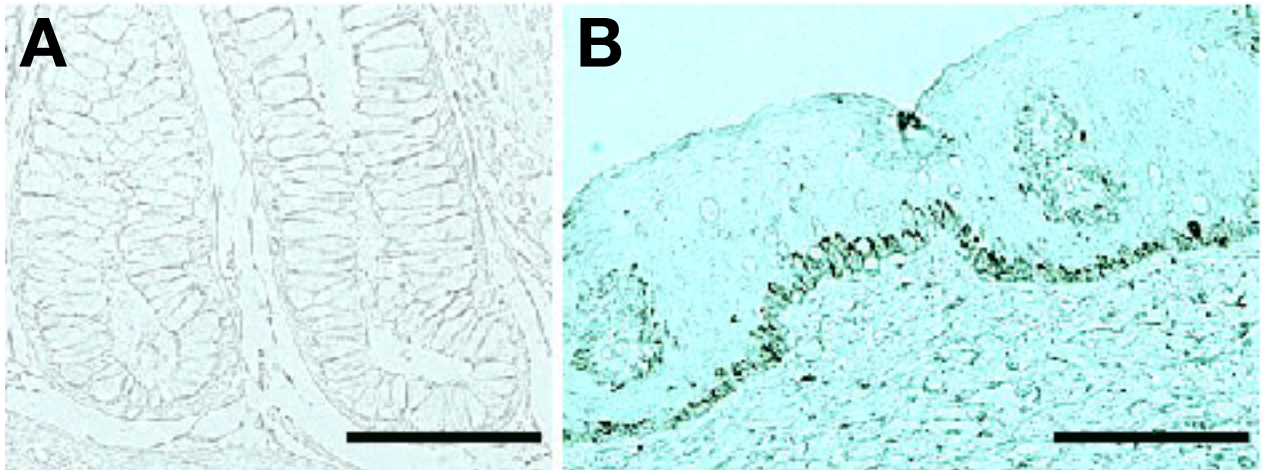


Fig. 1. Immunohistochemical topoisomerase I protein expression in normal colorectal mucosa adjacent to tumor (A) and in normal skin (B). Bar = 200 μ m.

Results

Topo I expression in tumors and in non-cancerous tissues

Topo I protein expression was not detected in normal colorectal mucosa. But it was detected

in normal cells in basal layer of the skin adjacent to rectal cancer of patients who had undergone amputation of the rectum (Fig. 1). Topo I immunostaining was mainly located in the nucleus of cancer cells (Fig. 2).

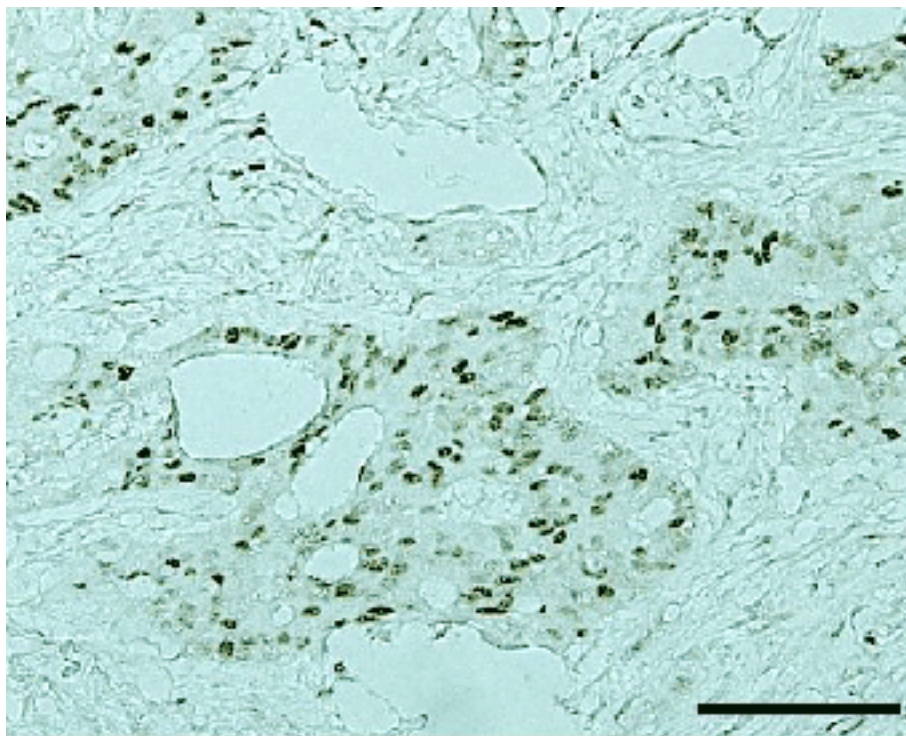


Fig. 2. Immunohistochemical topoisomerase I protein expression in advanced colorectal cancer. Strong nuclear expression of the protein is noted. Bar = 200 μ m.

Table 1. Topoisomerase I expression and clinicopathological findings

		Number of patients	Topoisomerase I		P
			Negative	Positive	
Location of tumor	Colon	55	29	26	0.383
	Rectum	49	30	19	
Histopathology	Well-differentiated type	54	39	15	0.001
	Moderately or poorly differentiated type	50	20	30	
Dukes' classification	A or B	41	29	12	0.020
	C	63	30	33	

Correlation with Topo I protein expression and clinicopathological findings of patients

Topo I protein expression was detected in 45 of 104 patients (43.2%). Topo I protein expression was more frequently detected in moderately differentiated type or poorly differentiated type colorectal carcinoma than in well-differentiated carcinoma (Table 1). Moreover, Topo I was positive in only 12 of 41 patients (29.3%) in Dukes' A and B, while in 33 of 63 patients (52.4%) in Dukes' C (Table 1).

Topo I protein expression and prognosis of patients

The overall and disease-free 5-year survival rates of 104 patients with colorectal cancer were 64.9% and 75.5%, respectively. The disease-free 5-year survival rate of 50 patients with moderately differentiated or poorly differentiated carcinoma (63.6%) was lower than that of 54 patients with well differentiated carcinoma (86.4%, $P = 0.01$). And the disease-free 5-year survival rate of 63 patients in Dukes' C (64.4%) was lower than that of 41 patients in Dukes' A and B (94.3%, $P = 0.002$). Moreover, when the 104 patients were divided into two sub-groups according to their immunohistochemical findings, the disease-free 5-year survival rate of the 45 Topo I-positive patients (62.7%) was significantly lower than that of the 59 Topo I-negative patients (84.3%, $P = 0.005$, Fig. 3).

In order to understand whether Topo I protein expression is one of the prognostic factors of

patients with colorectal cancer or not, variables (histological type, Dukes' classification, Topo I protein expression) were analyzed by Cox's proportional hazards regression model. Analysis determined that Topo I protein expression was not a prognostic factor independent from Dukes' classification (Table 2).

Topo I protein expression of tumors and effectiveness of adjuvant chemotherapy in patients with Dukes' C carcinoma

Out of the 63 Dukes' C patients, 47 were treated with 5-fluorouracil-based chemotherapy post-operatively. An oral dose of 600 mg/day of 1-(2-tetrahydrofuryl)-5-fluorouracil/uracil (1:4) (UFT; Taiho Pharmaceutical, Tokushima, Japan) was administered to these patients for at least 1 year. Postoperative chemotherapy was not performed on 13 patients because of advanced age

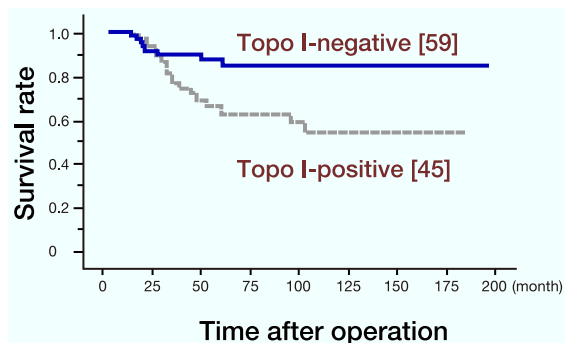


Fig. 3. The disease-free 5-year survival curve of 45 topoisomerase I (Topo I)-positive patients (dotted line) is significantly lower than that of 59 Topo I-negative patients (solid line) ($P = 0.005$). [], number of patients.

Table 2. Multivariate survival analysis in patients with colorectal cancer

Variable	Hazard ratio	95% Confidential interval	P
Histological type of tumors			
Moderately and poorly differentiated types versus well-differentiated types	1.379	0.548–3.467	0.495
Dukes' classification			
C versus A and B	3.822	1.307–14.09	0.044
Topoisomerase I protein expression			
Positive versus negative	2.007	0.908–4.937	0.083

(over 75) and 3 patients refused postoperative chemotherapy. At the end of 2006, 23 Dukes' C patients died from cancer recurrence. Fifteen were in the chemotherapy group (32%, 15/47) and 8 were in the non-chemotherapy group (50%, 8/16). Thus, 5-fluorouracil-based postoperative chemotherapy reduced the percentage of cancer recurrence from 50% to 32% in Dukes' C patients ($P = 0.2$).

Among the 23 Dukes' C patients who died from cancer recurrence, 16 were treated with Topo I inhibitor (CPT-11) just after detection of the recurrence. We observed that among the 16, 12 had Topo I-positive primary tumors, while 4 had Topo I-negative primary tumors. The survival periods just after the start of CPT-11 chemotherapy ranged from 2 to 43 months. Of these 16 patients, CPT-11 chemotherapy prolonged the survival of 12 patients who had Topo I-positive primary tumors over the 4 patients who had Topo I-negative primary tumors (Table 3).

Table 3. Survival time just after starting CPT-11 chemotherapy in 16 patients with recurrent colorectal cancer

	Number of patients	50% Survival period† (month)	P
Topoisomerase I-negative	4	4	0.041
Topoisomerase I-positive	12	12	

† After starting chemotherapy.

Discussion

It is known that Topo I expression is not observed in normal colon tissue, but we found Topo I-positive cells in basal cell layer of normal skin adjacent to rectal cancer. Bauman et al. (1997) and Hafian et al. (2004) reported that the expression of Topo I and Topo II protein were detected in normal tissue with proliferating cells including normal tonsil and normal skin. So, closed correlation between Topo I protein expression and cell proliferative activity is thought to be possible. In this study, we demonstrated the frequent occurrence of Topo I expression in surgically resected colorectal cancer (43.2%). We found that the percentage of patients who had Topo I-positive tumors was much higher in Dukes' C than in Dukes' A and B. Moreover, Topo I protein expression was more frequently detected in moderately or poorly differentiated adenocarcinomas than in well differentiated carcinomas. These findings indicate that Topo I expression closely correlated with tumor progression and histopathological differentiation in colorectal cancer. Also in human sarcomas, the incidence of detectable Topo I protein expression increased with tumor progression (Caleman et al., 2002). However, Staley et al. (1999) reported no correlation between Topo I expression and Dukes' classification in 29 patients with colorectal cancer. But the number of patients in their study was too small to elucidate a clear correlation between Topo I protein expression and tumor progression in colorectal cancer. Further investigation is needed.

We found that the 5-fluorouracil-based post-operative chemotherapy prolonged the survival of patients with Dukes' C colorectal cancer instead of Topo I protein expression of tumors. Recently, Topo I inhibitors have frequently been used in the treatment of advanced or recurrent colorectal cancers (Paradiso et al., 2004). But correlation between clinical effectiveness of Topo I inhibitors and tumor expression of Topo I protein has not been well studied in human colorectal cancer patients. In our study, we found that when CPT-11 chemotherapy had been used for patients with recurrent tumors, the survival periods of patients who had Topo I-positive primary tumors were significantly prolonged than those of patients who had Topo I-negative primary tumors. In vitro, it has been shown that tumors with a higher level of Topo I protein responded to Topo I inhibitors, but RNA expression was not predictive for the anti-proliferative effect of Topo I inhibitors (McLeod et al., 1996; Jansen et al., 1997). However, ATP-binding cassette transporters called ABCG2 or carboxylesterases have been reported to correlate with tumor sensitivity against Topo I inhibitors (Pavillard et al., 2002; Sanghani et al., 2003; Wierdl et al., 2003; Candeil et al., 2004). In order to prolong the survival of patients with advanced or recurrent colorectal cancer or to prevent ineffective chemotherapy for such patients, clinical importance of Topo I protein expression in colorectal cancer, especially sensitivity of tumors to Topo I inhibitors, should be investigated extensively.

Reference

- 1 Bauman ME, Holden JA, Brown KA, Harker WG, Perkins SL. Differential immunohistochemical staining for DNA topoisomerase IIa and b in human tissues and for DNA topoisomerase IIb in non-Hodgkin's lymphomas. *Mod Pathol* 1997;10:168–175.
- 2 Candeil L, Gourdiere I, Peyron D, Vezzio N, Copois V, Bibeau F, et al. ABCG2 overexpression in colon cancer cells resistant to SN38 and in irinotecan-treated metastasis. *Int J Cancer* 2004;109:848–854.
- 3 Coleman LW, Rohr LR, Bronstein IB, Holden JA. Human DNA topoisomerase I: an anticancer drug target present in human sarcomas. *Human Pathol* 2002;33:599–607.
- 4 de Gramont A, Figuer A, Seymour M, Homerin M, Hmissi A, Cassidy J, et al. Leucovorin and fluorouracil with or without oxaliplatin as first-line treatment in advanced colorectal cancer. *J Clin Oncol* 2000;18:2938–2947.
- 5 Douillard JY, Cunningham D, Roth AD, Navarro M, James RD, Karasek P, et al. Irinotecan combined with fluorouracil compared with fluorouracil alone as first-line treatment for metastatic colorectal cancer: a multicentre randomised trial. *Lancet* 2000;355:1041–1047.
- 6 Dukes CE, Bussey HJR. The spread of rectal cancer and its effect on prognosis. *Br J Cancer* 1958;12:309–320.
- 7 Giaccone G, van Ark-Otte J, Scagliotti G, Capranico G, van der Valk P, et al. Differential expression of DNA topoisomerase in nonsmall cell lung cancer and normal lung. *Biochem Biophys Acta* 1995;1264:337–346.
- 8 Goldwasew F, Bae I, Valenti M, Torres K, Pommier Y. Topoisomerase I-related parameters and camptothecin activity in the colon carcinoma cell lines from the National Center Institute and anticancer screen. *Cancer Res* 1995;55:2116–2121.
- 9 Gupta M, Fujimori A, Pommier Y. Eukaryotic DNA topoisomerase I. *Biochem Biophys Acta* 1995;1262:1–14.
- 10 Hafian H, Venteo L, Sukhanova A, Nabiev I, Lefevre B, Pluot M. Immunohistochemical study of DNA topoisomerase I, DNA topoisomerase IIa, p53, and Ki-67 in oral preneoplastic lesions and oral squamous cell carcinomas. *Human Pathol* 2004;35:745–751.
- 11 Hsiang Y, Lihou MG, Liu LF. Arrest of replication forks by drug-stabilized topoisomerase I-DNA cleavable complexes as a mechanism of cell killing by camptothecin. *Cancer Res* 1989;49:5077–5082.
- 12 Husain I, Mohler JL, Seigler HF, Besterman JM. Elevation of topoisomerase I messenger RNA, protein, and catalytic activity in human tumors: demonstration of tumor-type specificity and implications for cancer chemotherapy. *Cancer Res* 1994;54:539–546.
- 13 Jansen WJ, Zwart B, Hulscher ST, Giaccone G, Pinedo HM, Boven E. CPT-11 in human colon-cancer cell lines and xenografts: Characterization of cellular sensitivity determinants. *Int J Cancer* 1997;70:335–340.
- 14 McLeod HL, Keith WN. Variation in topoisomerase I gene copy number as a mechanism for intrinsic drug sensitivity. *Br J Cancer* 1996;74:508–512.
- 15 O'Leary J, Muggia FM. Camptothecins: a review of their development and schedules of administration. *Eur J Cancer* 1998;34:1500–1508.
- 16 Paradiso A, Xu J, Mangia A, Chiriatti A, Simone G,

- Zito A, et al. Topoisomerase-I, thymidylate synthase primary tumour expression and clinical efficacy of 5-FU/CPT-11 chemotherapy in advanced colorectal cancer patients. *Int J Cancer* 2004;111:252–258.
- 17 Pavillard V, Agostini C, Richard S, Charasson V, Montaudon D, Robert J. Determinants of cytotoxicity of irinotecan in two human colorectal tumor cell lines. *Cancer Chemother Pharmacol* 2002;49:329–335.
- 18 Rasheed ZA, Rubin EH. Mechanisms of resistance to topoisomerase I-targeting drugs. *Oncogene* 2003; 22:7296–7304.
- 19 Rowinsky EK, Adjei A, Donehower RC, Gore SD, Jones RJ, Burke PJ, et al. Phase I and pharmacodynamic study of the topoisomerase I-inhibitor topotecan in patients with refractory acute leukemia. *J Clin Oncol* 1994;12:2193–2203.
- 20 Sanghani SP, Quinney SK, Fredenburg TB, Sun Z, Davis WI, Murry DJ, et al. Carboxylesterases expressed in human colon tumor tissue and their role in CPT-11 hydrolysis. *Clin Cancer Res* 2003;9:4983–4991.
- 21 Staley BE, Samowitz WS, Bronstein IB, Holden JA. Expression of DNA topoisomerase I and DNA topoisomerase II-a in carcinoma of colon. *Mod Pathol* 1999;12:356–361.
- 22 Vallböhmer D, Iqbal S, Yang DY, Rhodes KE, Zhang W, Gordon M, et al. Molecular determinants of irinotecan efficacy. *Int J Cancer* 2006;119:2435–2442.
- 23 van der Zee AG, de Jong S, Keith WN, Hollema H, Bloonstra H, de Vries EG. Quantitative and qualitative aspects of topoisomerase I and II alpha and beta in untreated and platinum/cyclophosphamide treated malignant ovarian tumors. *Cancer Res* 1994;54:749–755.
- 24 Wierdl M, Wall A, Morton CL, Sampath J, Danks MK, Schuetz JD, et al. Carboxylesterase-mediated sensitization of human tumor cells to CPT-11 cannot override ABCG2-mediated drug resistance. *Mol Pharmacol* 2003;64:279–288.
- 25 Sanghani SP, Quinney SK, Fredenburg TB, Sun Z, Davis WI, Murry DJ, et al. Carboxylesterases expressed in human colon tumor tissue and their role in CPT-11 hydrolysis. *Clin Cancer Res* 2003;9:4983–4991.

Received August 24, 2007; accepted September 20, 2007

Corresponding author: Masahide Ikeguchi, MD