

A Novel Technique for the Avoiding Catheter Dislodgment Caused by Atrio-Ventricular Dissociation after Elimination of the Accessory Pathway

Toshimitsu Suga, Osamu Igawa and Ichiro Hisatome

First Department of Internal Medicine, Faculty of Medicine, Tottori University, Yonago 683-0826 Japan

We hypothesized that the atrio-ventricular (AV) dissociation occurring after elimination of the accessory pathway conduction during right ventricular (RV) pacing made the stability of the ablation catheter worse. We confirmed this hypothesis by using a pacing model. As a simulation model, sequential ventriculo-atrial (VA) pacing was designed and studied in 20 patients without VA conduction. Prior to the sequential VA pacing, 3 catheters were positioned in the RV, right atrium (RA) and at the tricuspid valve annulus (TVA), respectively. The sequential VA pacing consisted of continuous RV pacing at a cycle length of 600 ms and RA pacing. The RA was paced at an interval of 125 ms following the RV pacing. To induce AV dissociation, RA pacing was abruptly terminated during continuous sequential VA pacing. We observed the motion of the catheter tip on the TVA before and after RA pacing using fluoroscopy in the 30° right anterior oblique (RAO) and 45° left anterior oblique (LAO) views. The catheter tip position in the end-systolic and end-diastolic phases was confirmed in each projection, and the distance of the catheter tip between these 2 phases was measured. The mean value of the catheter tip distance between the 2 phases obtained with sequential VA pacing and fusion beats was 7.5 ± 3.2 and 21.0 ± 8.3 mm in the RAO ($P < 0.001$) and 8.0 ± 4.5 and 19.0 ± 8.6 mm in the LAO views ($P < 0.001$), respectively. Further, we proposed a new pacing maneuver to stabilize the ablation catheter position after the elimination of accessory pathway conduction. Using sequential VA pacing, we examined catheter tip movement during RF current delivery in 6 patients with the concealed Wolff-Parkinson-White syndrome. During RF current delivery, catheter dislodgment did not occur in any patients after the accessory pathway was eliminated when no fusion beats occurred. In conclusion, AV dissociation occurring after elimination of the accessory pathway conduction during RV pacing worsened the stability of the ablation catheter. Furthermore, a new pacing maneuver during the RF application provided a useful method for maintaining stable catheter position for catheter ablation of accessory pathways.

Key words: catheter dislodgment; sequential pacing; radiofrequency catheter ablation; Wolff-Parkinson-White syndrome

In the case of manifest anterograde accessory pathway conduction, radiofrequency (RF) energy is usually delivered during sinus rhythm to the site with the shortest atrio-ventricular (AV) interval and/or an accessory pathway potential

(Twidale et al., 1991; Calkins et al., 1992; Silka et al., 1992; Bashir et al., 1993; Grimm et al., 1994). In the case of concealed retrograde accessory pathways, evaluation of the local electrogram is meaningful only during the retro-

Abbreviations: AV, atrio-ventricular; CS, coronary sinus; HRA, high right atrium; LAO, left anterior oblique; RA, right atrium; RAO, right anterior oblique; RF, radiofrequency; RV, right ventricle/ventricular; TVA, tricuspid valve annulus; VA, ventriculo-atrial; VCS, ventriculo-CS; VRA, ventriculo-HRA

grade accessory pathway conduction occurring during either orthodromic tachycardia or right ventricular (RV) pacing, and the RF energy is delivered during either the tachycardia or RV pacing (Okumura et al., 1993; Li et al., 1994). In all cases, during RF catheter ablation of accessory pathways, once the elimination of the accessory pathway conduction is observed, the RF energy application should be continued for a prolonged length of time in order to assure a permanent cure, even if there is a prompt loss of the accessory pathway conduction within 2 to 3 s. Unfortunately, if the catheter movement occurs at the time of the elimination of the accessory pathway, in particular with concealed retrograde accessory pathways in which it is necessary to use RV pacing, the RF energy application cannot be continued and the temporary loss of accessory pathway conduction can make subsequent mapping and ablation difficult. There have been many trials attempted to avoid such an occurrence (Li et al., 1994; Okumura et al., 1993); however, the cause of this accident has not yet been reported. In this study, we hypothesized that the AV dissociation after the elimination of the accessory pathway during RV pacing made the stability of the ablation catheter worse. We confirmed this by using a pacing model that simulated the condition when RF energy is delivered to the concealed accessory pathways during the constant RV pacing. Further, we proposed new pacing maneuvers, which we called sequential ventriculo-high right atrium (VRA) pacing or ventriculo-coronary sinus (VCS) pacing, to stabilize the ablation catheter position after the elimination of the accessory pathway. Therefore, we would like to describe our preliminary experience with this technique.

Patients and Methods

Pacing model

Sequential ventriculo-atrial (VA) pacing was designed as a model to simulate the condition when RF energy is delivered to concealed accessory pathways during constant RV pacing.

The study population consisted of 20 consecutive patients (12 males, 8 females; mean age, 42 ± 24 years) who underwent electrophysiological examination between July 1996 and September 1997 in the Division of Cardiology, First Department of Internal Medicine, Faculty of Medicine, Tottori University. Out of the 20 patients, 7 had the sick sinus syndrome and 13 were successfully ablated Wolff-Parkinson-White syndrome patients. In this examination, we confirmed that no patients had VA conduction or structural heart disease. Antiarrhythmic drugs were discontinued for at least a 5-fold period of their half-life in all patients. The research was performed after completion of the diagnostic study in the sick sinus syndrome patients and after successful ablation in the Wolff-Parkinson-White patients.

Prior to the sequential VA pacing, two 5-Fr quadripolar (5 mm interelectrode spacing) catheters (Cordis Webster, Baldwin Park, CA) were introduced via the inferior vena cava and positioned in the right atrium (RA) and RV. A 7-Fr quadripolar catheter with a large tip electrode (electrode length 4 mm; Cordis Webster) was introduced via the inferior vena cava and positioned on the tricuspid valve annulus (TVA). One indicator that the catheter on the TVA, which represented the RF catheter, was satisfactorily positioned, was the presence of clear and discernible equal atrial and ventricular components of the local electrogram recorded from the distal pair of electrodes of the catheter. Simultaneously performed right coronary artery angiography supported the existence of satisfactory positioning. The sequential VA pacing consisted of continuous RV pacing at a cycle length of 600 ms and RA pacing. The RA was paced at an interval of 125 ms following the RV pacing. Both pacing impulses constantly collided in the normal conduction system (Fig. 1 A). RV pacing was obtained by abrupt termination of the RA pacing during continuous sequential VA pacing. The sinus node function recovered due to the termination of the RA pacing. The different rates of the sinus rhythm and RV pacing prevented constant collision of the impulses (Fig. 1B). In this manner, we were able to simulate the same condition as that observed during

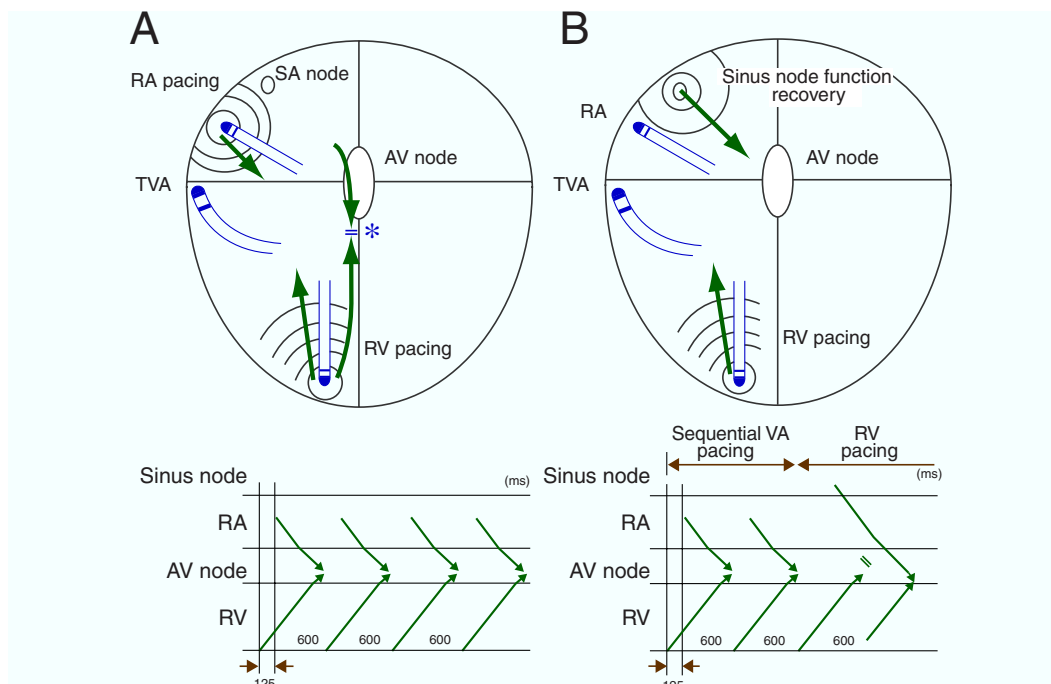


Fig. 1. Illustrations showing the method of sequential ventriculo-atrial (VA) and right ventricular (RV) pacings, with the conduction patterns during sequential VA pacing (**A**) and during RV pacing (**B**). See the text for details. AV, atrio-ventricular; SA, sinoatrial; RA, right atrium; TVA, tricuspid valve annulus.

elimination of accessory pathways. In other words, sequential VA pacing was the condition before the elimination of accessory pathway, and sequential RV pacing, after the elimination. During sequential VA or RV pacing, the movement of the catheter tip on the TVA, was observed using fluoroscopy in the 30° right anterior-oblique (RAO) and 45° left anterior-oblique (LAO) views. The position of this catheter tip during the end-systolic and end-diastolic phases was confirmed in each projection, and the distance between the position of the catheter tip in these 2 phases was measured. Body surface and intracardiac electrograms were monitored and recorded with an EP Amp and EP Lab (Quinton, Seattle, WA). Pacing was performed with a cardiac stimulator (SEC-3102, Nihon Kohden, Tokyo, Japan) using rectangular stimuli at twice the diastolic threshold and a pulse width of 2 ms. The distal pair of electrodes of RV and RA were used for stimulation, while the proximal pair of electrodes were used for recording the local bipolar electrogram.

RF ablation under sequential VRA or VCS pacing

The pacing technique was used in 6 patients in whom either right or left concealed accessory pathways was electrophysiologically diagnosed. Out of the 6 patients (4 males, 2 females; mean age, 42 ± 24 years), 4 patients had left-sided and 2 right-sided accessory pathways. Using this sequential VA pacing, we were able to design a method that would mimic the VA conduction, that occurs with accessory pathways during RV pacing, even after the elimination of the accessory pathway conduction. When the accessory pathway was located on the left side, RF ablation was performed using an RF generator (CAT 500, Central Inc., Ichikawa, Japan) while delivering sequential VRA pacing. The RV-high RA (HRA) pacing interval was programmed to be the maximum interval in which the atrial wave front propagating from the HRA pacing site did not hide the earliest activation of the left atrium through the accessory pathway.

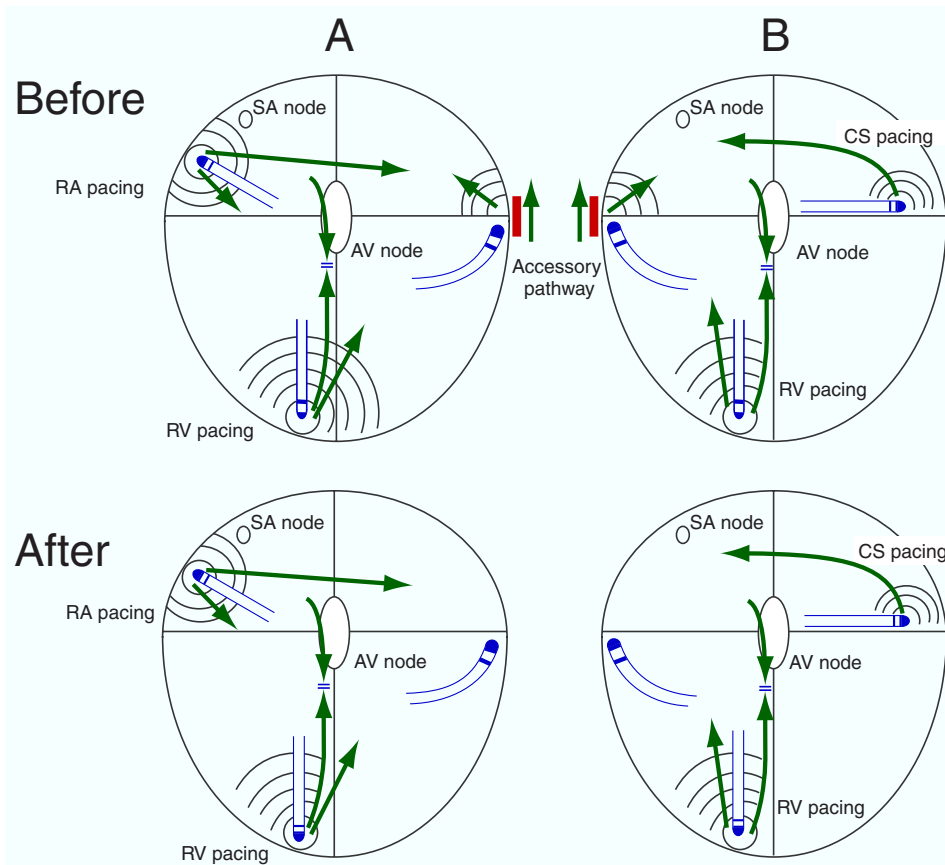


Fig. 2. Illustration showing the activation sequences before and after the elimination of accessory pathway conduction when sequential ventriculo-high right atrium pacing (**A**) or ventriculo-coronary sinus (CS) pacing (**B**) is applied during the radiofrequency application. **A:** A left-sided accessory pathway case. **B:** A right-sided accessory pathway case. See the text for details. AV, atrio-ventricular; RA, right atrium; RV, right ventricular; SA, sinoatrial.

In other words, the VA interval was programmed in order to minimize the atrial activation through the accessory pathway to just only local activation (minimum atrial activation) (Fig. 2A). If the accessory pathway was located on the right side, we performed RF ablation during sequential VCS pacing (Fig. 2B). If elimination of the accessory pathway conduction was observed, the RF energy application was continued for 60 s at 20 W. Before and after elimination of the accessory pathway, the movement of the ablation catheter tip on the mitral or tricuspid valve annulus, was observed using fluoroscopy in the 30° RAO and 45° LAO views. The position of this catheter tip during

the end-systolic and end-diastolic phases was confirmed in each projection, and the distance between the position of the catheter tip in these 2 phases was measured over 5 consecutive beats. All patients gave written informed consent to participate in this study.

Data and Statistical Analysis

All data were presented as mean \pm SD. Continuous variables were compared using Student's *t*-test for paired samples. A probability of < 0.05 was considered statistically significant.

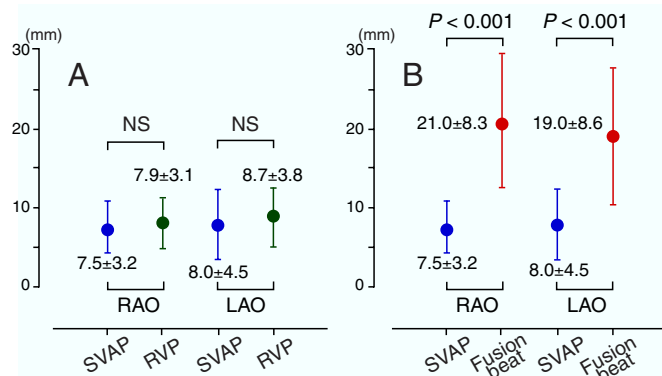


Fig. 3. The distance between the location of the catheter tip on the tricuspid valve annulus in the end-systolic and end-diastolic phases. **A** shows mean values of the distance during sequential VA pacing (SVAP) and RV pacing (RVP), not including fusion beats. **B** shows mean values of the distance during SVAP and fusion beats. LAO, 45° left anterior oblique view; NS, not significant; RAO, 30° right anterior oblique view.

Results

Sequential VA pacing

The catheter located on the TVA was positioned on the right posterior-lateral TVA in all patients. The catheter tip movement revealed that the TVA motion was weak and constant during sequential VA pacing, and had a tendency to be strong during RV pacing regardless of patients respirations. The mean value of the distance that the catheter tip moved from its position in the end-systolic phase to that in the end-diastolic phase during sequential VA or RV pacing, except during fusion beats, for 10 beats was 7.5 ± 3.2 mm and 7.9 ± 3.1 mm in the RAO projection and 8.0 ± 4.5 mm and 8.7 ± 3.8 mm in the LAO projection, respectively. However, there was no significant difference between the values obtained during sequential VA or RV pacing in either projection (Fig. 3A). However, when a fusion beat during RV pacing resulting from a supraventricular beat propagating down the normal AV conduction system occurred, there was strong and abrupt movement of the TVA catheter. The mean value of the distance the catheter moved during the fusion beats was 21.0 ± 8.3 mm and 19.0 ± 8.6 mm in the RAO

and LAO projections, respectively. As a result, the distances observed with the fusion beats were substantially longer than those during sequential VA pacing ($P < 0.001$) (Fig. 3B). In 6 patients the local electrogram recorded from the distal pair of electrodes of the TVA catheter during fusion beats with RV pacing varied from that during sequential VA pacing.

Typical examples of TVA motion during sequential VA pacing and a fusion beat are shown in Figs. 4 and 5. In Fig. 4, RA pacing at an interval of 125 ms following the RV pacing was discontinued abruptly during constant RV pacing at a cycle length of 600 ms. This indicated that a fusion beat resulting from a sinus beat propagating down the normal AV conduction system occurred when the sinus node function had recovered after stopping the RA pacing (see the asterisk). The local electrogram recorded from the distal pair of electrodes of the TVA catheter altered with the fusion beats. Depicted in Fig. 5 is the fluoroscopy taken during right coronary artery angiogram in the 30° RAO and 45° LAO views during sequential VA pacing (Fig. 5A) and RV pacing when a fusion beat occurred (Fig. 5B). The 2 images of the end-systolic and end-diastolic phases were superimposed during each pacing attempt. The distance of the catheter tip movement on the TVA was measured. The distance of the catheter tip movement during sequential VA pacing was 4.9 mm and 4.2 mm in the RAO and LAO projections, respectively (Fig. 5A). On the other hand, the distance during a fusion beat was 16.7 mm and 13.9 mm in the RAO and LAO projections, respectively (Fig. 5B). This indicated that the distance of the catheter tip moved during the fusion beat was longer than that during sequential VA pacing. The above results indicate that fusion beat will play the pivotal role for the dislodgment of catheter tip.

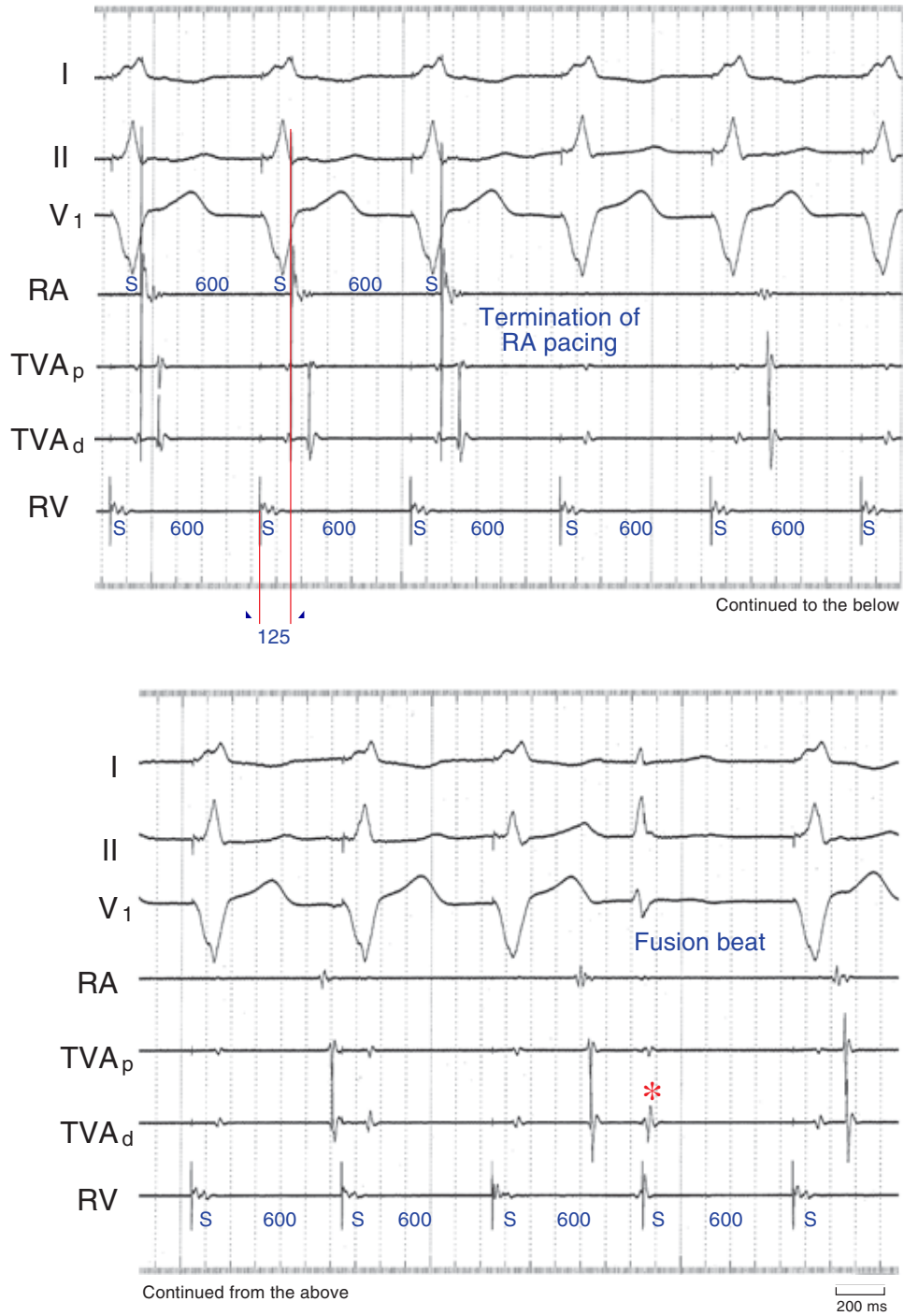


Fig. 4. Surface electrocardiographic (ECG) and intracardiac ECG tracings recorded during sequential ventriculo-atrial (VA) pacing. The figure demonstrates, from top to bottom, ECG leads I, II and V₁; intracardiac electrograms recorded from the right atrium (RA), the proximal (TVA_p) and distal (TVA_d) bipoles of the quadripolar catheter placed at the tricuspid valve annulus (TVA) and the right ventricle (RV). See the text for details. All values are in ms. The paper speed is 75 mm/s. S, stimulus artifact.

RF ablation under sequential VRA or VCS pacing

We hypothesized that sequential VA pacing can attenuate the dislodgment of the catheter tip during RF ablation. As shown in Table 1, in all patients, there was no significant difference between values obtained before and after elimination of the accessory pathway in either projection. All accessory pathways were successfully eliminated without dislodgment of the ablation catheter.

Typical examples of intracardiac electrograms recorded during RF ablation of a left-

sided accessory pathway is shown in Fig. 6. After obtaining a stable catheter position with appropriate localization of the accessory pathway as judged by the earliest retrograde atrial activation on the local electrogram during RV pacing, sequential VRA pacing was initiated before the application of RF current. In this case, sequential VRA pacing was performed at a pacing drive cycle length of 500 ms and a VA interval of 60 ms. During sequential VRA pacing, after no change in the local activation sequence at the distal coronary sinus (CS₁₋₂) was confirmed, implying that conduction was through the accessory pathway, RF current was applied while monitoring the change in the

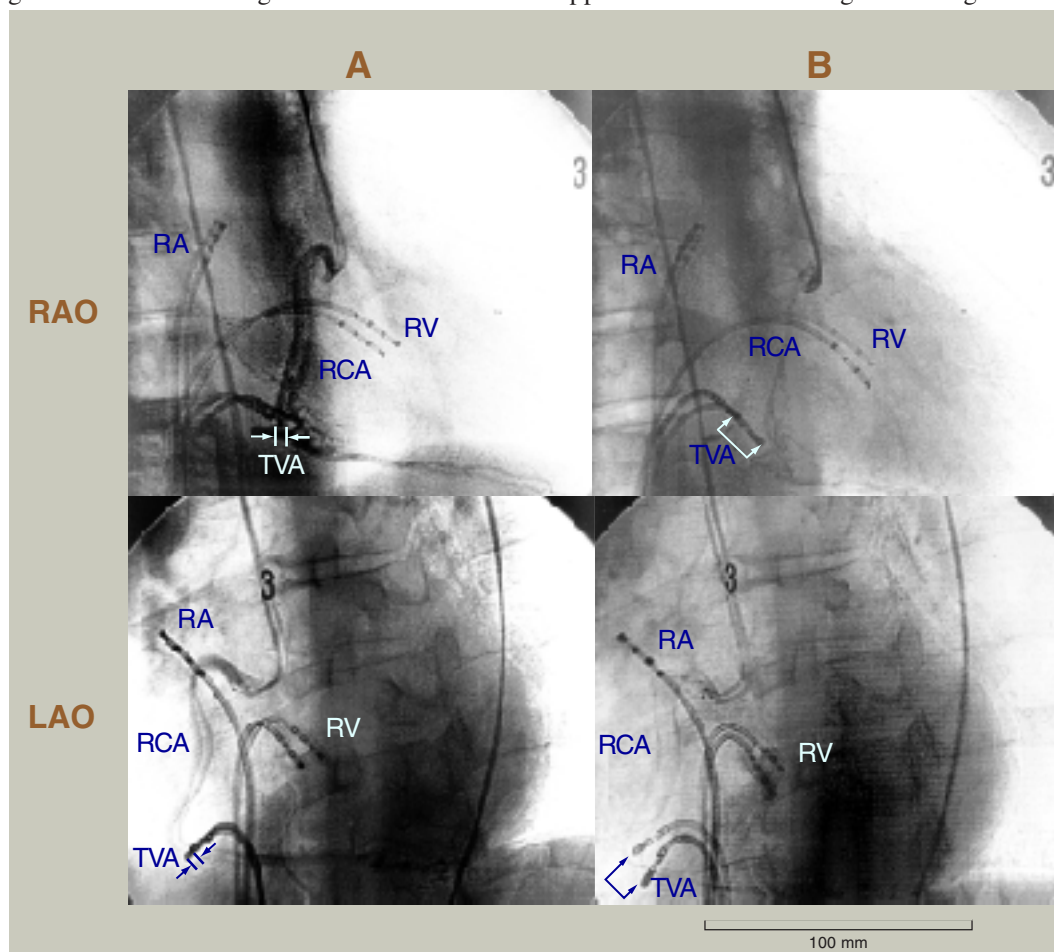


Fig. 5. The fluoroscopy images of the right coronary artery angiogram in the 30° right anterior oblique (RAO) and 45° left anterior oblique (LAO) projections during sequential ventriculo-atrial pacing (A) and right ventricular pacing when a fusion beat occurred (B). Two images of the diastolic and systolic phases are superimposed during each pacing attempt. See the text for details. RA, catheter in the right atrium; RCA, right coronary artery; RV, catheter in the right ventricle; TVA, catheter on the tricuspid valve annulus.

Table 1. The distance between the positions of the catheter tip

Patient Number	Location of the accessory pathway	Before elimination of the accessory pathway		After elimination of the accessory pathway	
		RAO	LAO	RAO	LAO
1	Left antero-lateral	15.8 ± 1.4	16.1 ± 1.7	16.3 ± 1.2	16.3 ± 1.3
2	Left antero-lateral	15.8 ± 1.4	16.1 ± 0.8	16.3 ± 1.2	16.3 ± 1.6
3	Left postero-lateral	12.4 ± 1.2	10.1 ± 0.9	12.3 ± 1.2	11.3 ± 0.9
4	Right lateral	12.8 ± 0.8	7.7 ± 0.8	12.0 ± 1.0	7.6 ± 1.0
5	Right antero-lateral	9.0 ± 1.2	11.1 ± 1.3	9.3 ± 1.6	11.3 ± 1.4
6	Left septal	13.5 ± 1.4	15.3 ± 1.2	12.8 ± 1.2	14.8 ± 1.0
Mean		13.2 ± 2.5	12.7 ± 3.6	13.1 ± 2.7	12.9 ± 3.5

Data are expressed as mean ± SD in mm.

LAO, 45° left anterior oblique view; RAO, 30° right anterior oblique view.

There is no significant difference between values obtained before and after elimination of the accessory pathway in either projection.

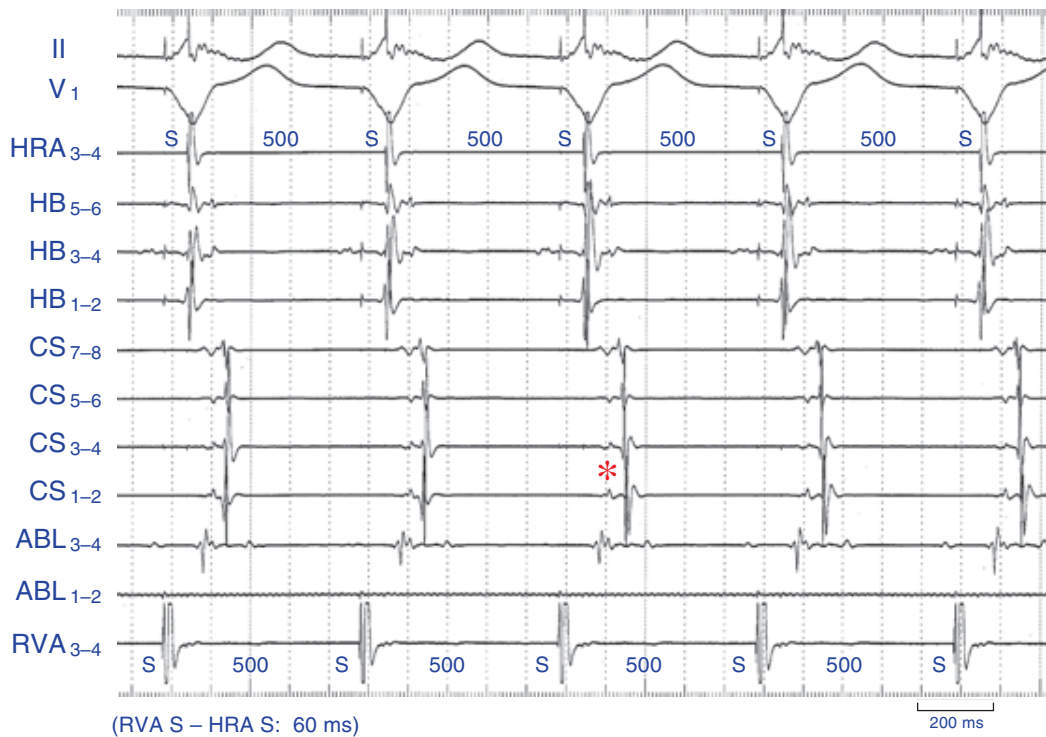


Fig. 6. Surface electrocardiographic (ECG) tracings and intracardiac electrograms recorded during radiofrequency (RF) catheter ablation of a concealed left lateral accessory pathway during sequential ventriculo-high right atrium (HRA) pacing (VRA pacing). This figure demonstrates, from top to bottom, ECG leads II and V₁; intracardiac electrograms recorded from the HRA, proximal (HB₅₋₆) and distal (HB₁₋₂) His-bundle region, proximal (CS₇₋₈) and distal (CS₁₋₂) coronary sinus (CS), proximal (ABL₃₋₄) and distal (ABL₁₋₂) bipoles of the ablation catheter, and right ventricular apex (RVA). The earliest retrograde atrial activation prior to ablation is observed at the distal CS (CS₁₋₂). The HRA is paced constantly at an interval of 60 ms following the constant right ventricular (RV) pacing with a drive cycle length of 500 ms before the application of RF current. In this situation, the 2 activation waves in the left atrium, one through the accessory pathway during the RV pacing and the other from the right atrium resulting from the sequential VRA pacing, collided between CS₃₋₄ and CS₅₋₆. Note the change in the activation sequence of the atrium at CS₁₋₂ within 5 s of initiation of the RF energy application as indicated by the asterisk. This change exhibited by lengthening of the ventriculo-atrial interval at CS₁₋₂ during sequential VRA pacing, shows that the accessory pathway conduction is eliminated by the RF current. The paper speed is 100 mm/s. S, stimulus artifact.

retrograde atrial activation pattern. After observing that the local atrial activation sequence at CS₁₋₂ indicated that there was a loss of VA conduction over the accessory pathway 5 s after RF current delivery had begun, and the RF current was continued for 60 s. During the RF application, the ablation catheter had a stable position and no fusion beats occurred.

Other examples from a patient with a right-sided accessory pathway are shown in Fig. 7. In this case, sequential VCS pacing was performed at a cycle length of 500 ms and with a VA interval of 90 ms. The distal (TVA₁₋₂) and proximal (TVA₃₋₄) bipoles of the quadripolar catheter placed near the accessory pathway

reflected the activation of the atria through the accessory pathway during the right ventriculo-basal pacing. When a change in the local atrial activation sequence in the TVA was observed at 7 s after initiation of RF current delivery, indicating loss of VA conduction over the accessory pathway, the RF application was continued for 60 s. During the RF application, the position of the ablation catheter was stable and no fusion beats occurred.

Complications

There were no complications, such as hemodynamic disturbance or serious arrhythmias

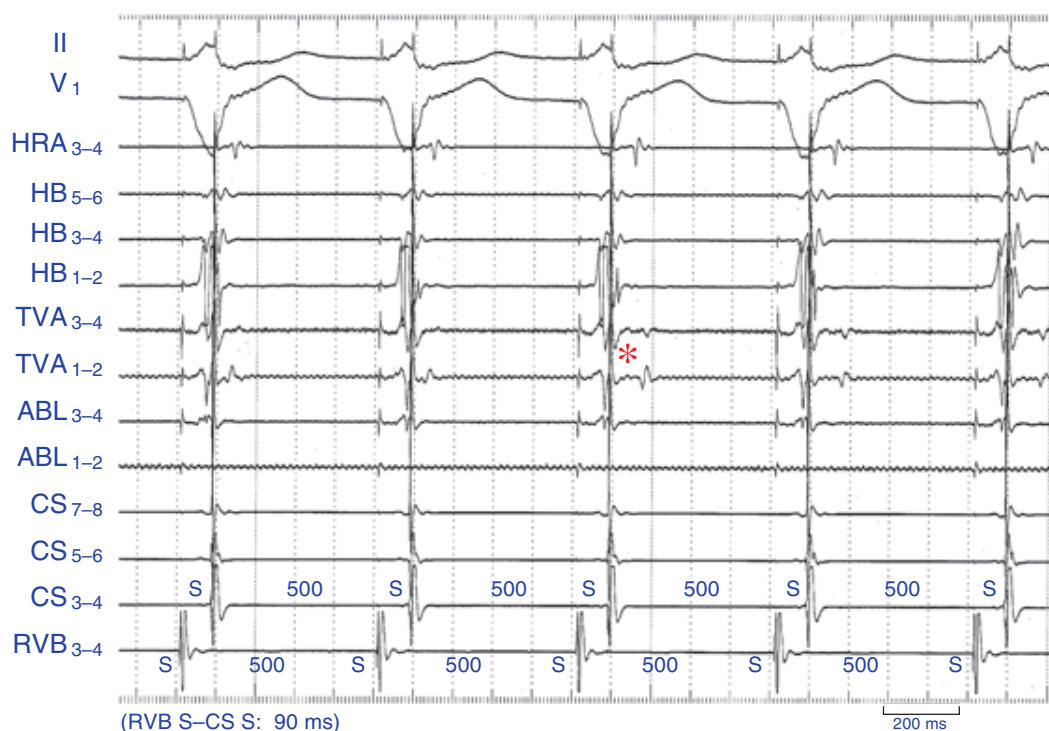


Fig. 7. Surface electrocardiographic (ECG) tracings and intracardiac electrograms recorded during radiofrequency (RF) catheter ablation of a concealed right lateral accessory pathway during ventriculo-coronary sinus (VCS) pacing. This figure demonstrates, from top to bottom, ECG leads II and V₁; intracardiac electrograms recorded from the high right atrium (HRA), proximal (HB₅₋₆) and distal (HB₁₋₂) His-bundle region, proximal (TVA₃₋₄) and distal (TVA₁₋₂) bipoles of the quadripolar catheter placed at the tricuspid valve annulus (TVA), proximal (ABL₃₋₄) and distal (ABL₁₋₂) bipoles of the ablation catheter, proximal (CS₇₋₈) and distal (CS₃₋₄) coronary sinus (CS), and right ventriculo-basal (RVB) region. The TVA catheter was placed near the accessory pathway. The CS is constantly paced before the application of the RF current at an interval of 90 ms after the constant RVB pacing stimulus with a drive cycle length of 500 ms. Note the change in the activation sequence of the atrium at TVA₁₋₂ within 7 s after initiating the RF application, as indicated by the asterisk. This change shows that the accessory pathway conduction is eliminated by the RF current. The paper speed is 100 mm/s. S, stimulus artifact.

during the procedure. No accidents involving impedance rises while delivering energy through the ablation catheter occurred during the sequential VRA or VCS pacing.

Discussion

The main findings of this study

In the present study, we found that: i) the AV dissociation after elimination of accessory pathway conduction during the delivery of the RF energy when using RV pacing made the stability of ablation catheter worse; and ii) sequential VRA or VCS pacing during the RF application provided a useful method for maintaining a stable catheter position for catheter ablation of accessory pathways.

The relationship between AV dissociation and the stability of the ablation catheter

In this study, the manner of AV annulus motion was probably related to ventricular contraction rather than the atrial contraction. In visually comparing the TVA motion during sequential VA pacing with that during RV pacing on fluoroscopy, we could not find any significant difference in the degree of movement of the catheter on the TVA between these 2 pacing methods. However, when a fusion beat during RV pacing occurred, the distances observed with the fusion beats were substantially longer than those during sequential VA pacing. In other words, the AV annulus motion during AV dissociation occurring during the RV pacing exhibited little change when no fusion beats occurred. On the other hand, when fusion beats during RV pacing occurred, there was a strong and abrupt movement of the catheter on the TVA. Occetta et al. (1990) reported that adequate ventricular diastolic filling was important for the efficiency of the subsequent ventricular ejection. Dritsas et al. (1993) reported that the magnitude of the beat-to-beat variability in the stroke volume during VVI pacing reflects the relative contribution of the atrium to LV filling. Kuo et al. (1987) reported that left ventricular

compliance increased the dependence of cardiac output on atrial filling during late diastole. In our case, ventricular filling was increased by atrial filling in order to maintain AV synchrony with fusion beats. Furthermore, the fusion beats in which the QRS complex on the electrocardiogram was narrower than that with RV pacing, had a reduced ventricular activation time. The ejection timing for each ventricle with fusion beats was shorter than with RV pacing. Therefore RV pacing altered the ventricular contraction during fusion beats. We considered the cause of the ablation catheter dislodgment might be due to the change in the manner of AV annulus motion produced by the alteration in the ventricular contraction pattern during fusion beats.

The novel technique for maintaining catheter position during RF application

Li et al. (1994) reported that entrainment of orthodromic tachycardia during RF application was useful for maintaining catheter position for accessory pathway ablation during atrioventricular reentrant tachycardia. Entrainment of orthodromic tachycardia with RV pacing prevents this abrupt slowing when the orthodromic tachycardia is terminated. However, if the rate of the tachycardia is relatively fast, the patients may experience discomfort due to worsening of the hemodynamic status from the rapid RV pacing at a rate faster than the tachycardia, making it impossible to continue to ablate the pathway. By using sequential VA pacing, none of the patients complained of any symptoms (data not shown). In this study, the rate of sequential VA pacing was not so fast, and we felt that the sequential VA pacing did not affect the hemodynamic status.

RV pacing before the elimination of the accessory pathway conduction by the RF energy delivery also prevents catheter dislodgment empirically. We believed this was due to the stability of the catheter from VA conduction occurring through the accessory pathway during the RV pacing. However, after elimination of accessory pathway conduction, we usually observed catheter dislodgment. This is because

the ventricular contraction pattern changes from VA conduction due to RV pacing to AV conduction in fusion beat when the sinus node function recovers after the accessory pathway is eliminated. If retrograde AV nodal conduction occurs during parahisian pacing, there should be little chance of dislodgment since fusion beats also should not occur (Buitelir and Morady, 1997). Clinically, in the case of retrograde conduction propagating through both the AV node and accessory pathway, RV pacing during ablation of accessory pathways was effective in preventing dislodgment of the ablation catheter when no fusion beats occurred. On the other hand, in the case of retrograde conduction propagating through the accessory pathway alone, when fusion beats during RV pacing occurred, there was a strong and abrupt movement of the ablation catheter. As a result, elimination of the accessory pathway may cause dislodgment of the catheter.

Sequential VRA or VCS pacing during RF application

sequential VRA or VCS pacing which inhibits the sinus node function during RF energy delivery is necessary in order to prevent catheter dislodgment. We felt that sequential VRA and VCS pacings were good optional techniques. During the sequential VRA or VCS pacing, dislodgment of the ablation catheter did not occur when elimination of the accessory pathway conduction occurred during the RF application in any of the patients. Fusion beats did not occur since the atrium was activated by the constant atrial pacing instead of propagation through the accessory pathway from the RV pacing following elimination of the accessory pathway conduction. However, strictly speaking, the local activation pattern changed from that of conduction over the accessory pathway to that of atrial pacing, and in a patient with a septal accessory pathway this change was remarkable. We believed that using sequential pacing was better than RV pacing alone, when the accessory pathway was eliminated, because it prevented fusion beats.

One of the problems with this technique was

that the optimal RV-HRA or RV-CS pacing interval was necessary to program for various accessory pathway locations. The most optimal pacing interval was programmed to the maximum interval at which the atrial wave front propagating from the HRA or CS pacing site did not hide the earliest activation of the left or right atrium through the accessory pathway. Further, this pacing interval, which was programmed in order to minimize the local atrial activation through the accessory pathway, minimized the change in the manner of AV annulus motion when the atrium was activated by constant atrial pacing instead of through the accessory pathway from the RV pacing following the elimination of the accessory pathway conduction.

Conclusion

The AV dissociation after the elimination of the accessory pathway conduction during RF energy delivery while using RV pacing worsened the stability of the ablation catheter. During the RF application, sequential VA pacing was better than RV pacing, because no fusion beats occurred. Furthermore, sequential VRA or VCS pacing during the RF application provides a useful method for maintaining stable catheter position for catheter ablation of accessory pathways. This technique may be especially useful in patients with concealed accessory pathways and no retrograde conduction over the AV node.

References

- 1 Bashir Y, Heald SC, Katritsis D, Hammouda M, Camm AJ, Ward DE. Radiofrequency ablation of accessory atrioventricular pathways: predictive value of local electrogram characteristics for the identification of successful target sites. *Br Heart J* 1993;69:315-321.
- 2 Buitelir M, Morady F. Radiofrequency catheter ablation of left free wall accessory pathways. In: Singer I, ed. *Interventional electrophysiology*. Baltimore: Williams & Wilkins; 1997. p. 179-275.
- 3 Calkins H, Kim YN, Schmaltz S, Sousa J, el-Atassi R, Leon A, et al. Electrogram criteria for

- identification of appropriate target sites of radiofrequency ablation of accessory atrioventricular connection. *Circulation* 1992;85:565–573.
- 4 Dritsas A, Joshi J, Webb SC, Athanassopoulos G, Oakley CM, Nihoyannopoulos P. Beat-to-beat variability in stroke volume during VVI pacing as predictor of hemodynamic benefit from DDD pacing. *Pacing Clin Electrophysiol* 1993;16:1713–1718.
 - 5 Grimm W, Miller J, Josephson ME. Successful and unsuccessful sites of radiofrequency catheter ablation of accessory atrioventricular connections. *Am Heart J* 1994;128:77–87.
 - 6 Kuo LC, Quinones MA, Rokey R Sartori M, Abinader EG, Zoghbi WA. Quantification of atrial contribution to left ventricular filling by pulsed doppler echocardiography and the effects of age in normal and diseased hearts. *Am J Cardiol* 1987;59:1174–1178.
 - 7 Li HG, Klein GJ, Zardini M, Thakur RK, Morillo CA, Yee R. Radiofrequency catheter ablation of accessory pathways during entrainment of AV re-entrant tachycardia. *Pacing Clin Electrophysiol* 1994;17:590–594.
 - 8 Occhetta E, Piccinino C, Francalacci G, Magnani A, Bolognese L, Devecchi P, et al. Lack of influence of atrioventricular delay on stroke volume at rest in patients with complete atrioventricular block and dual chamber pacing. *Pacing Clin Electrophysiol* 1990;13:916–926.
 - 9 Okumura K, Yamabe H, Yasue H. Radiofrequency catheter ablation of accessory pathway during entrainment of the atrioventricular reciprocating tachycardia. *Am J Cardiol* 1993;72:188–193.
 - 10 Silka MJ, Kron J, Halperin BD, Griffith K, Crandall B, Oliver RP, et al. Analysis of local electrogram characteristics correlated with successful radiofrequency catheter ablation of accessory atrioventricular pathways. *Pacing Clin Electrophysiol* 1992;15:1000–1007.
 - 11 Twidale N, Wang X, Beckman KJ, McClelland JH, Moulton KP, Prior MI, et al. Factors associated with recurrence of accessory pathway conduction after radiofrequency catheter ablation. *Pacing Clin Electrophysiol* 1991;14:2042–2048.

Received August 21, 2000; accepted September 11, 2000

Corresponding author: Dr. Toshimitsu Suga