

Initial Experience of Robot-Assisted Adrenalectomy in Japan: What is the Optimal Selection of Robotic Forceps for Adrenalectomy?

Shuichi Morizane,* Masashi Honda,* Ryutaro Shimizu,* Shogo Teraoka,* Tetsuya Yumioka,* Noriya Yamaguchi,* Hideto Iwamoto,* Katsuya Hikita* and Atsushi Takenaka*

*Division of Urology, Department of Surgery, School of Medicine, Faculty of Medicine, Tottori University, 683-8503, Japan

ABSTRACT

Minimally invasive adrenalectomy is the preferred technique for managing adrenal tumors. Laparoscopic adrenalectomy is widely performed and covered by insurance in Japan, but robot-assisted adrenalectomy is not. To investigate the best forceps combinations for performing robot-assisted adrenalectomy safely, we performed robot-assisted adrenalectomy for two left and two right adrenal adenomas using different robotic forceps combinations (bipolar forceps, monopolar curved scissors, Vessel Sealer Extend, and SynchroSeal) for each case. Although we evaluated a small number of RAs, lower blood loss was observed in patients where the vessel sealing devices were used. The extent of dissection is small for adrenalectomy, and robotic bipolar vessel sealing tools may not be necessary, especially for the small adrenal tumors. However, considering the risk benefits, the combination of forceps with Vessel Sealer Extend (by the left arm) and monopolar curved scissors (by the right arm) will become one of the best forceps combinations for performing robot-assisted adrenalectomy safely.

Key words adrenalectomy; forceps; robotic surgery

Minimally invasive laparoscopic and robotic adrenalectomy are preferred techniques for managing adrenal tumors.¹ The Food and Drug Administration approved the da Vinci robotic system for general laparoscopic procedures in the United States in 2000. The first robot-assisted adrenalectomy (RA) case was reported in 2001.² In Japan, laparoscopic adrenalectomy (LA) has been widely performed and covered by insurance since 1996, but RA has not. However, RA has been increasingly used worldwide because of its reported advantages, such as less blood loss, shorter hospital

stay, and lower intraoperative complications than open adrenalectomy (OA) and LA.^{3–11} In addition, it has been suggested that RA may have a benefit in large adrenal tumors (>6 cm), obese patients, and patients with previous abdominal surgery compared with LA.^{12–14} Furthermore, RA for pheochromocytoma achieves better outcomes than LA in terms of safety and efficacy.¹¹

However, a major issue is the high cost of RA compared to LA and OA,^{5, 8, 15} and the long-term oncological outcomes of RA are still unknown.¹⁶ Although it is difficult to uniformly discuss medical costs because of the differences in medical systems in each country, some studies report the cost-effectiveness of robotic surgery by shortening the operation time, hospital stay, and reducing the number of robotic forceps.^{4, 6, 17, 18} This study investigated the optimal robotic forceps combination in RA and performed surgeries using different robotic forceps combinations for each case.

MATERIALS AND METHODS

RA was performed using a da Vinci Xi surgical system (Intuitive Surgical, Sunnyvale, CA) at our hospital between June 2020 and December 2021. The cases included two left adrenal adenomas and two right adrenal adenomas (Table 1). The patients were placed in a lateral decubitus mild jackknife position with table flexion. Then, trocars were placed. Figure 1 shows port placement for RA on the right side. The same is done on the left side. Since we have safely performed robot-assisted partial nephrectomy with such a port arrangement, we adopted the same port placement for RA. First, a camera port was placed approximately 1–2 cm cephalad from the umbilicus at a point slightly beyond the outer edge of the rectus abdominis muscle (Fig. 1A). Then, we drew a line from the camera port parallel to the line directly across from the umbilicus and drew another line 30 degrees to the head. A perpendicular line was drawn to a point 4 cm from the camera port and a point 8 cm from the camera port for use as the left arm and right arm port. A 12-mm AirSeal access port was placed as the foot side assistant port. A 5-mm port was placed as the head side assistant port as necessary. The insufflation pressure was 8 mmHg, and the renal vessels were targeted with the da Vinci Xi.

Corresponding author: Shuichi Morizane, MD, PhD
morizane@tottori-u.ac.jp

Received 2022 March 18

Accepted 2022 April 22

Online published 2022 May 23

Abbreviations: LA, laparoscopic adrenalectomy; OA, open adrenalectomy; RA, robot-assisted adrenalectomy; VSE, Vessel Sealer Extend

Table 1. Clinical characteristics and surgical outcomes

Clinical characteristics	Case 1	Case 2	Case 3	Case 4
Age (years)	43	69	41	46
Gender	Male	Male	Male	Female
Side of tumor	Left	Right	Right	Left
Primary disease	Cushing's syndrome	Pheochromocytoma	Primary aldosteronism	Cushing's syndrome
Size of tumor (mm)	34	22	15	14
Body mass index (kg/m ²)	23.5	24.5	20.2	19.4
Surgical outcomes				
Total operating time (min)	118	126	88	95
Console time (min)	56	60	37	53
Estimated blood loss (mL)	5	50	5	5
Post-operative hospital stays (days)	9	8	6	8
Complications Clavien-Dindo (≥ Grade III)	None	None	None	None
Robotic forceps				
Robotic right arm	Monopolar scissors Vessel Sealer Extend	Monopolar scissors	Monopolar scissors	Monopolar scissors
Robotic left arm	Maryland bipolar forceps	Fenestrated bipolar forceps	Vessel Sealer Extend	SynchroSeal
Cost for forceps	\$1,161	\$605	\$877	\$877

All RAs were performed via a transperitoneal approach by the console surgeon (A.T.) and the assistant surgeon (S.M.). After mobilizing the descending colon, spleen, and pancreas from the anterior surface of the left kidney, the central vein of the adrenal gland was clipped. The adrenal glands were then removed through the left adrenalectomy. The ascending colon was similarly mobilized when necessary in the right adrenalectomy. The resected adrenal gland was placed in a retrieval bag and removed from the camera port.

Ethics statement

The institutional review board of Tottori University Hospital approved this study (IRB No. 21J003). The study conforms to the provisions of the Declaration of Helsinki.

RESULTS

The details of the four RA cases performed in this study are shown in Table 1. The mean tumor size was 21.3 (range: 14–34) mm, the console time was 51.5 (range: 37–60) minutes, and the mean blood loss was 16.3 (range: 5–50) mL. There were no perioperative Grade

III or higher Clavien–Dindo classification complications. We used Maryland bipolar forceps in the left arm, monopolar curved scissors in the right arm, and Vessel Sealer Extend (VSE) in the right arm in case 1 (Fig. 1B). We used fenestrated bipolar forceps in the left arm and monopolar curved scissors in the right arm in case 2 (Fig. 1C). In case 3, the VSE was used in the left arm (Fig. 1D), and in case 4, the SynchroSeal was used in the left arm. Although we evaluated a small number of RA cases, we were able to perform RAs safely and without complications in all patients using various forcep combinations, and we observed a trend of less loss of blood in patients using the vessel sealing devices.

DISCUSSION

We assessed the optimal robotic forceps selection for RA, albeit in a small number of cases. To the best of our knowledge, this report is the first that describes optimal robotic forceps use with the VSE (by the left arm) during RA. Several reports suggest that the problem with robotic surgery is its high cost compared to laparoscopic or open surgery; the same is true for RA.^{5, 8, 15, 17, 19} Brandao et al. reported RA using three

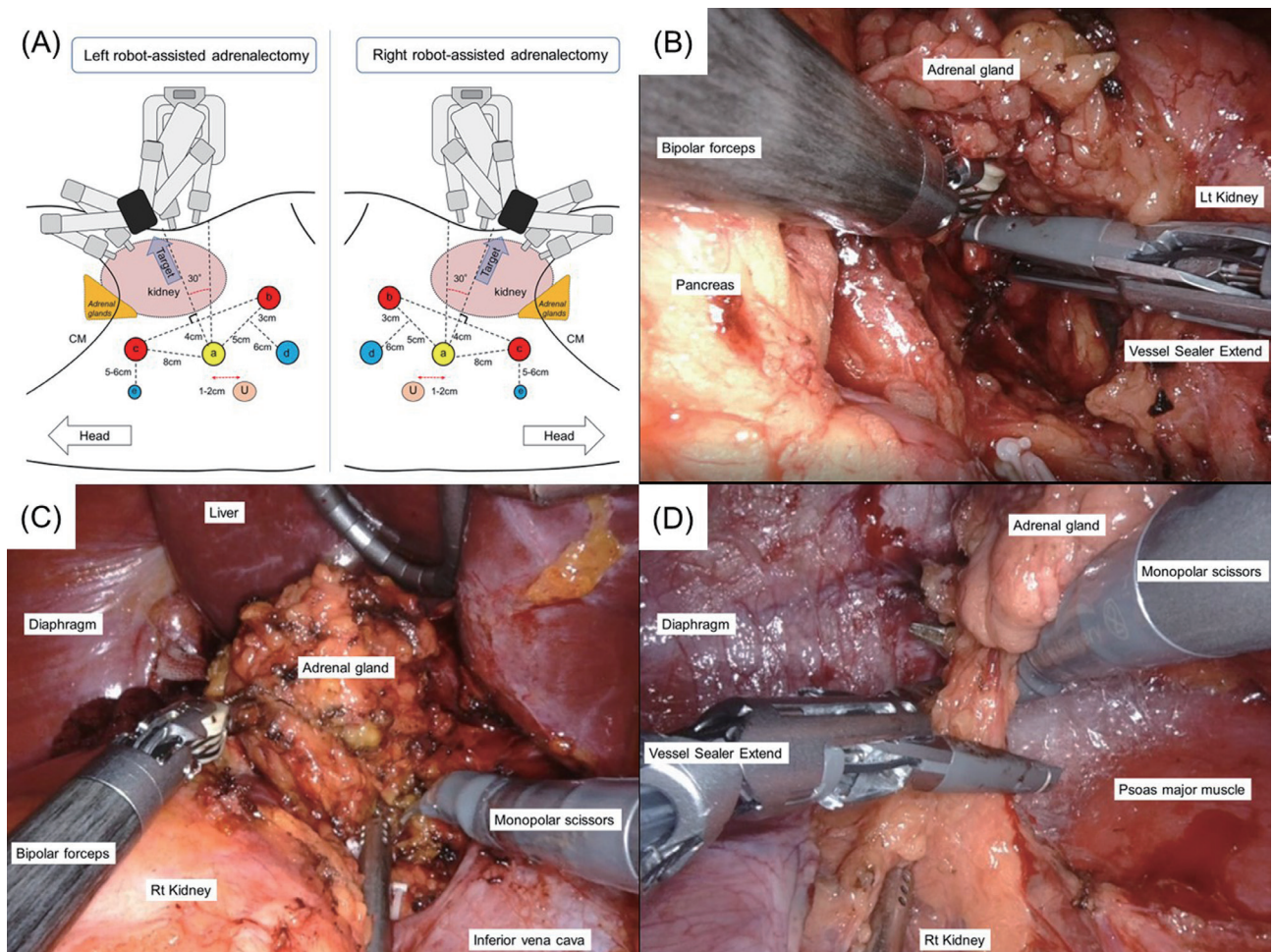


Fig. 1. (A) Trocar placement and targeting the direction in left and right adrenalectomy using the da Vinci Xi[®]: a: 8-mm camera port, b: 8-mm robotic left arm port, c: 8-mm robotic right arm port, d: 12-mm assistant port, e: 5-mm assistant port; if required, CM: costal margin. (B) Switching from monopolar scissors to Vessel Sealer Extend in the right arm coagulation and dissection of periadrenal tissue. The left arm uses bipolar forceps (case 1). (C) Coagulation and dissection of periadrenal tissue using bipolar forceps on the left arm and monopolar scissors on the right arm (case 2). (D) Coagulation and dissection of periadrenal tissue using Vessel Sealer Extend on the left arm and monopolar scissors on the right arm (case 3).

robotic forceps.²⁰ We agree that using more robotic forceps may be a safer approach to RA. However, the adrenal gland is a small organ, and with some ingenuity, it is possible to perform RA safely with two robotic forceps, as we did. While a left RA could be performed with two robotic forceps and one assistant port, we believe that a right RA would require an additional assistant port to elevate the liver. We also believe that a single 5-mm assistant port would make it difficult for the assistant to insert the gauze in case of bleeding and that at least one 12-mm assistant port would be necessary for RA. As a result, the same or one more port is required for RA compared to LA.

With the development of the bipolar vessel sealer, surgical energy devices other than electrocautery are used during LA in addition to electrocautery. Although

the number of patients in this study is too small and no statistical advantage could be found, the estimated blood loss in case 2 without vessel sealing devices was 50 ml, and the estimated blood loss in the other three cases with vessel sealing devices was 5 ml. There are many procedures in RA to dissect fatty tissues, including small blood vessels (superior suprarenal artery, middle suprarenal artery, inferior suprarenal artery, suprarenal vein, inferior phrenic vein) and lymphatic vessels, such as the dissection of Gerota's fascia. We believe that robotic bipolar vessel sealing devices can be useful for adrenalectomy and robot-assisted radical nephroureterectomy, which we have previously reported.²¹ Fewer robotic forceps and fewer energy devices can lower the costs.¹⁸ However, we believe that using the VSE is preferable for the reasons mentioned before, especially

for the large adrenal tumors. Compared to the VSE, the SynchroSeal grasps delicate tissue better, but we felt that it was inferior in coagulation and incision—important factors in RA. For the small adrenal tumors, the forceps combination in case 2 may be enough. But we believe that the combination of forceps in case 3 may be the ideal selection of forceps for the large adrenal tumors in RA.

When using the VSE in the left arm, it is important to note that optimal tissue traction by the surgeon's right arm or an assistant is required when coagulating tissue with the left arm. It is also important for the console surgeon to communicate with the assistant closely. Under the Japanese medical insurance system, a fixed fee is paid to the hospital for each surgery, so the cost of robotic forceps and other materials for robotic surgery must be kept as low as possible. The use of an ultrasonic coagulation cutting device, etc., is additionally covered by medical insurance for \$261 in Japan. Therefore, using case 2 as a reference, the cost of case 1 was about \$556 higher than case 2. Case 3 and 4 resulted in a \$272 higher cost than case 2. Each country's healthcare system is different, so our ideas may not apply to all. However, Yiannakopoulou et al. reported that if RA reduces morbidity and mortality more than LA, it is also cost-effective.¹⁶ We performed the pilot study searching for the optimal selection of robotic forceps, especially focusing on VSE. Whether our method of selecting robotic forceps reduces complications and mortality needs to be verified in future large-scale studies. However, considering risk benefits, we expect our ideas to become one of the best forceps combinations especially for the large adrenal tumors during RA.

Acknowledgments: The authors want to thank the medical engineering, nursing, and anesthesia staff at Tottori University Hospital.

AUTHOR CONTRIBUTIONS

All authors agree with the manuscript's content and have read and approved the final manuscript. All authors contributed to the study's conception and design. Shuichi Morizane wrote the first draft of the manuscript and all authors commented on previous versions.

The authors declare no conflict of interest.

REFERENCES

- Nomine-Criqui C, Demarquet L, Schweitzer ML, Klein M, Brunaud L, Bihain F. Robotic adrenalectomy: when and how? *Gland Surg.* 2020;9(suppl 2):S166-72. DOI: 10.21037/gs.2019.12.11, PMID: 32175258
- Horgan S, Vanuno D. Robots in laparoscopic surgery. *J Laparoendosc Adv Surg Tech A.* 2001;11:415-9. DOI: 10.1089/10926420152761950, PMID: 11814134
- Aliyev S, Karabulut K, Agcaoglu O, Wolf K, Mitchell J, Siperstein A, et al. Robotic versus laparoscopic adrenalectomy for pheochromocytoma. *Ann Surg Oncol.* 2013;20:4190-4. DOI: 10.1245/s10434-013-3134-z, PMID: 23864309
- Nomine-Criqui C, Brunaud L, Germain A, Klein M, Cuny T, Ayav A, et al. Robotic lateral transabdominal adrenalectomy. *J Surg Oncol.* 2015;112:305-9. DOI: 10.1002/jso.23960, PMID: 26179549
- Inversini D, Manfredini L, Galli F, Zhang D, Dionigi G, Rausei S. Risk factors for complications after robotic adrenalectomy: a review. *Gland Surg.* 2020;9:826-30. DOI: 10.21037/gs.2020.04.10, PMID: 32775275
- Probst KA, Ohlmann CH, Saar M, Siemer S, Stöeckle M, Janssen M. Robot-assisted vs open adrenalectomy: evaluation of cost-effectiveness and peri-operative outcome. *BJU Int.* 2016;118:952-7. DOI: 10.1111/bju.13529, PMID: 27170225
- Brandao LF, Autorino R, Laydner H, Haber GP, Ouzaid I, De Sio M, et al. Robotic versus laparoscopic adrenalectomy: a systematic review and meta-analysis. *Eur Urol.* 2014;65:1154-61. DOI: 10.1016/j.eururo.2013.09.021, PMID: 24079955
- Samreen S, Fluck M, Hunsinger M, Wild J, Shabahang M, Blansfield JA. Laparoscopic versus robotic adrenalectomy: a review of the national inpatient sample. *J Robot Surg.* 2019;13:69-75. DOI: 10.1007/s11701-018-0808-3, PMID: 29696591
- Grogan RH. Current status of robotic adrenalectomy in the United States. *Gland Surg.* 2020;9:840-3. DOI: 10.21037/gs.2020.03.39, PMID: 32775277
- Sheetz KH, Claflin J, Dimick JB. Trends in the Adoption of Robotic Surgery for Common Surgical Procedures. *JAMA Netw Open.* 2020;3:e1918911. DOI: 10.1001/jamanetworkopen.2019.18911, PMID: 31922557
- Xia Z, Li J, Peng L, Yang X, Xu Y, Li X, et al. Comparison of Perioperative Outcomes of Robotic-Assisted vs Laparoscopic Adrenalectomy for Pheochromocytoma: A Meta-Analysis. *Front Oncol.* 2021;11:724287. DOI: 10.3389/fonc.2021.724287, PMID: 34604062
- Morelli L, Tartaglia D, Bronzoni J, Palmeri M, Guadagni S, Di Franco G, et al. Robotic assisted versus pure laparoscopic surgery of the adrenal glands: a case-control study comparing surgical techniques. *Langenbecks Arch Surg.* 2016;401:999-1006. DOI: 10.1007/s00423-016-1494-0, PMID: 27516077
- Aksoy E, Taskin HE, Aliyev S, Mitchell J, Siperstein A, Berber E. Robotic versus laparoscopic adrenalectomy in obese patients. *Surg Endosc.* 2013;27:1233-6. DOI: 10.1007/s00464-012-2580-1, PMID: 23073684
- Ragavan N, Selvaraj N, Raghavan D, Kamalakannan R, Govindaswamy TG, Balakrishnan AK, et al. Robot Assisted Laparoscopic Adrenalectomy: Does Size Matter? *Cureus.* 2020;12:e9887. DOI: 10.7759/cureus.9887, PMID: 32968553
- Feng Z, Feng MP, Feng DP, Solórzano CC. Robotic-assisted adrenalectomy using da Vinci Xi vs. Si: are there differences? *J Robot Surg.* 2020;14:349-55. DOI: 10.1007/s11701-019-00995-2, PMID: 31273609
- Yiannakopoulou E. Robotic assisted adrenalectomy: surgical techniques, feasibility, indications, oncological outcome and safety. *Int J Surg.* 2016;28:169-72. DOI: 10.1016/j.ijsu.2016.02.089, PMID: 26926087
- De Crea C, Arcuri G, Pennestri F, Paolantonio C, Bellantone R, Raffaelli M. Robotic adrenalectomy: evaluation of cost-effectiveness. *Gland Surg.* 2020;9:831-9. DOI: 10.21037/gs.2020.03.44, PMID: 32775276

- 18 Feng Z, Feng MP, Feng DP, Rice MJ, Solórzano CC. A cost-conscious approach to robotic adrenalectomy. *J Robot Surg.* 2018;12:607-11. DOI: [10.1007/s11701-018-0782-9](https://doi.org/10.1007/s11701-018-0782-9), PMID: [29388004](https://pubmed.ncbi.nlm.nih.gov/29388004/)
- 19 Materazzi G, Rossi L. Robot-assisted adrenalectomy: state of the art. *Updates Surg.* 2021;73:1131-46. DOI: [10.1007/s13304-020-00915-2](https://doi.org/10.1007/s13304-020-00915-2), PMID: [33175318](https://pubmed.ncbi.nlm.nih.gov/33175318/)
- 20 Brandao LF, Autorino R, Zargar H, Krishnan J, Laydner H, Akca O, et al. Robot-assisted laparoscopic adrenalectomy: step-by-step technique and comparative outcomes. *Eur Urol.* 2014;66:898-905. DOI: [10.1016/j.eururo.2014.04.003](https://doi.org/10.1016/j.eururo.2014.04.003), PMID: [24830625](https://pubmed.ncbi.nlm.nih.gov/24830625/)
- 21 Morizane S, Yumioka T, Iwamoto H, Hikita K, Honda M, Takenaka A. Initial Experience of Robot-Assisted Laparoscopic Nephroureterectomy in Japan: A Useful Technique Using a Vessel Sealing Device for Securing a Good Surgical Field and Efficient Sealing. *Asian J Endosc Surg.* 2022;15:458-62. PMID: [34877806](https://pubmed.ncbi.nlm.nih.gov/34877806/)