

# Invasive Fungal Rhinosinusitis with Orbital Apex Syndrome Leading to Brain Abscess in a Patient with Ulcerative Colitis

Yosuke Nakamura,\* Motoki Nakamori,\* Kazunori Fujiwara,\* Masamichi Kurosaki,† Kazuo Yashima‡ and Hiromi Takeuchi\*§

\*Division of Otolaryngology, Head and Neck Surgery, Department of Sensory and Motor Organs, School of Medicine, Faculty of Medicine, Tottori University, Yonago 683-8504, Japan, †Division of Neurosurgery, Department of Brain and Neurosciences, School of Medicine, Faculty of Medicine, Tottori University, Yonago 683-8504, Japan, ‡Division of Gastroenterology and Nephrology, Department of Multidisciplinary Internal Medicine, School of Medicine, Faculty of Medicine, Tottori University, Yonago 683-8504, Japan, and §Division of Otolaryngology, Tottori Red Cross Hospital, Tottori 680-8517, Japan

## ABSTRACT

We report the case of a 65-year-old male who presented with a 1-week history of right periorbital pain and progressive visual loss. He had a history of ulcerative colitis and was taking oral corticosteroids and mesalazine. Neurological and radiological examination demonstrated a rare case of invasive fungal rhinosinusitis that began with orbital apex syndrome. Initial endoscopic sinus surgery was performed and fungal culture identified *Aspergillus fumigatus*. Although antifungal treatment was started empirically before the operation, the patient had improved orbital pain but continued to have decreased right vision. Five months after the first surgical procedure, his condition deteriorated, including loss of consciousness, and a right temporal lobe abscess was found and surgically drained. Since then, the patient received antifungal treatment for 4 years without recurrence. Invasive fungal rhinosinusitis with orbital apex syndrome should be treated with long-term postoperative antifungal medication. It should be noted that even in immunosuppressive individuals such as ulcerative colitis, fungal rhinosinusitis with orbital apex syndrome may become severe.

**Key words** aspergillus; brain abscess; invasive fungal rhinosinusitis; orbital apex syndrome; ulcerative colitis

Glucocorticoid administration is a well-established treatment strategy for patients with ulcerative colitis. Patients who cannot be weaned off glucocorticoids may require an additional immunomodulatory medication, such as azathioprine. However, an important concern associated with systemic glucocorticoid therapy is the

dose-dependent increase in the risk of developing infectious diseases, especially those involving common bacterial, viral, parasitic and fungal species.<sup>1</sup> When used in combination with other immunosuppressive drugs, glucocorticoids may result in opportunistic infections by low-pathogenicity organisms; these conditions may either be newly acquired or due to reactivation of latent infections.<sup>2</sup> Immunosuppressive therapy is the main risk factor for opportunistic infections in patients with inflammatory bowel disease (IBD).<sup>3</sup> The risk of fungal infection appears to be low in IBD, but the morbidity and mortality are high.<sup>3</sup>

Orbital apex syndrome (OAS) is a syndrome that presents as ophthalmoplegia, proptosis, ptosis and vision decline.<sup>4</sup> In immunocompromised individuals, fungal rhinosinusitis can cause OAS, with *Aspergillus* being the most common pathogen.<sup>5</sup> Fungal rhinosinusitis is broadly divided into invasive forms and non-invasive forms, and invasive forms are rare. Opportunistic infections frequently involve the orbit and sinuses, with possible secondary intracranial extension. The prognosis of central nervous system (CNS) aspergillosis, especially intracerebral aspergillosis, is very poor, with high mortality ranging from 66% to 100%.<sup>6</sup>

To the best of our knowledge, CNS aspergillosis has not been previously reported in patients with IBD. Here we describe a patient with ulcerative colitis receiving a combination of systemic glucocorticoids and mesalazine, who developed a temporal brain abscess after intervention with invasive fungal rhinosinusitis. The patient has survived for more than 4 years following right temporal lobectomy and voriconazole maintenance therapy, although he experienced residual monocular blindness. In addition to the case presentation, we discuss the background and mechanism of brain abscess caused by invasive fungal rhinosinusitis.

## PATIENT REPORT

A 65-year-old Japanese male presented with a 1-month history of blurred vision. He also complained of right

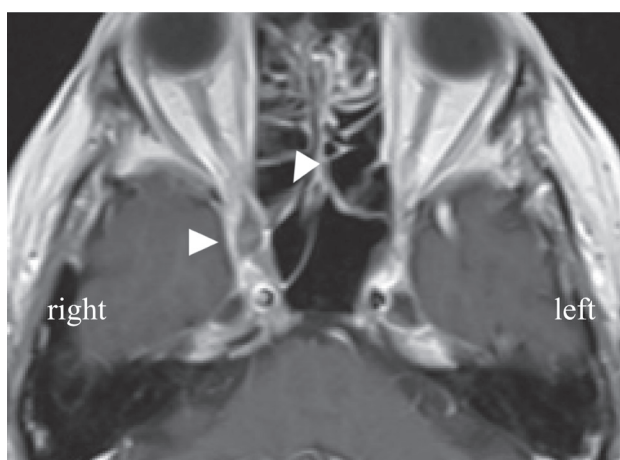
Corresponding author: Yosuke Nakamura, MD, PhD  
yosuken@tottori-u.ac.jp

Received 2021 February 16

Accepted 2021 March 1

Online published 2021 March 17

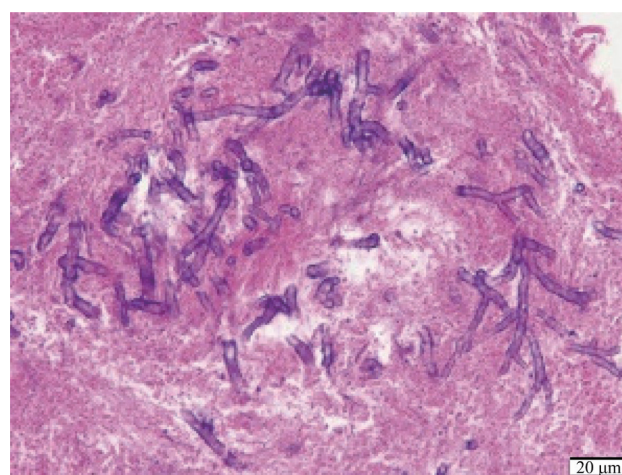
Abbreviations: CNS, central nervous system; ESS, endoscopic sinus surgery; IBD, inflammatory bowel disease; OAS, orbital apex syndrome; TDM, therapeutic drug monitoring



**Fig. 1.** Preoperative gadolinium-enhanced T1-weighted axial image. Arrowheads show an enhanced lesion on the right posterior ethmoid sinus extending to the orbital apex.

periorbital pain and progressive visual loss in the last week. He had no previous ophthalmic history. He had a 6-month history of ulcerative colitis (S1 Montreal classification). He was receiving prednisone 25 mg/day and mesalazine 4800 mg/day. Neurological examination revealed complete right-sided ophthalmoplegia with mydriasis, first trigeminal division hypoalgesia, diminished corneal reflex and counting fingers acuity in right eye. Magnetic resonance imaging showed an enhancing lesion on the right posterior ethmoid sinus extending to the orbital apex (Fig. 1). Blood tests showed only mild inflammation and a cerebrospinal fluid test showed no particular abnormalities. Biochemical examination revealed that the serum aspergillus galactomannan antigen,  $\beta$ -D-glucan, and *aspergillus*-specific antibody IgG levels were 0.2 (normal range < 0.5), 2.3 pg/mL (normal range < 11.0 pg/mL), and 0.1 AU/mL (negative range < 0.34), respectively. Given the examination results, OAS was considered. The presumptive diagnosis was either a skull base tumor or sinusitis that extended into the orbit and became an abscess. Cefazolin (3 g/day) and voriconazole (400 mg/day) were given by intravenous infusion. After a week of conservative treatment, a computed tomography scan showed that the lesion was still present, and therefore endoscopic sinus surgery (ESS) was performed via opening of the orbital apex.

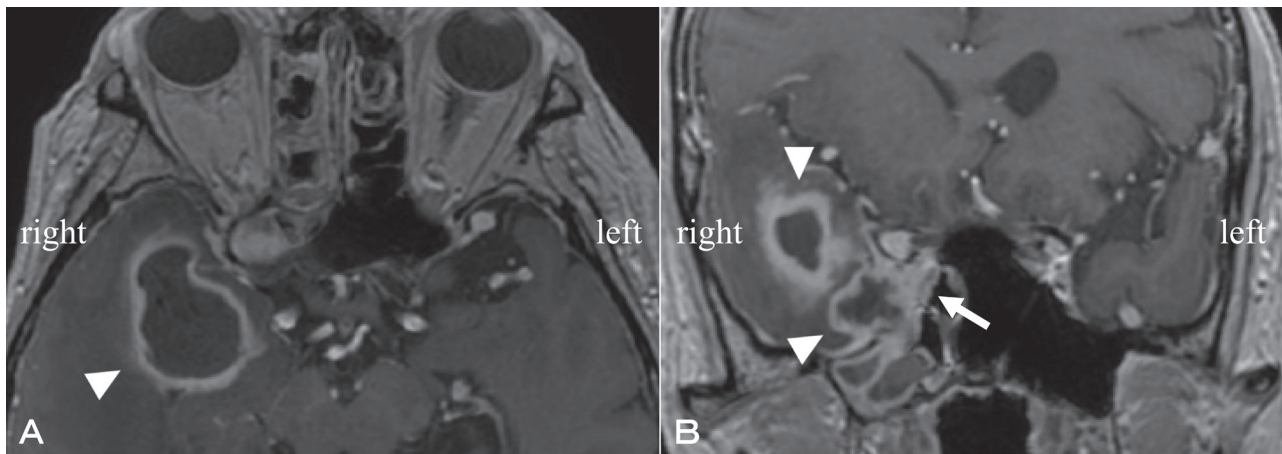
A fungal mass was discovered in the posterior ethmoid sinus, and an abscess was found at the apex of the orbit when the bone defect site was opened. Mucosal tissue revealed invasive, branching, septate fungal hyphae with minimal inflammation histologically (Fig. 2). Fungal culture identified *Aspergillus fumigatus* infection. Postoperative treatment included continued



**Fig. 2.** Photomicrography of the surgical specimen showing some hyphae of *Aspergillus fumigatus* in the orbital tissues (hematoxylin and eosin stain). Bar = 20  $\mu$ m.

voriconazole administration as well as sinus irrigation and dilatation. The patient's trigeminal pain resolved, but he had light perception in his right eye after a month. For treatment of ulcerative colitis, prednisolone was gradually reduced to 5 mg/day and mesalazine was maintained at 4800 mg/day. The patient was discharged after voriconazole was switched from intravenous to oral administration.

Five months after the first surgical procedure, the patient presented with episodes of right orbital pain and loss of consciousness. He was urgently hospitalized and imaging tests revealed a right temporal abscess (Fig. 3). He had his right eye blind. Chest X-ray was normal. In addition, the serum aspergillus galactomannan antigen and  $\beta$ -D-glucan levels were normal. He was still taking voriconazole, but therapeutic drug monitoring (TDM) for voriconazole had not been carried out for 3 months and the blood level of voriconazole had dropped to 0.4  $\mu$ g/mL. Despite puncture drainage and 3 weeks of antifungal treatment, a computed tomography scan still showed a residual abscess, and therefore complete right temporal lobectomy was performed with simultaneous ESS. Histological examination of the sinuses and the bottom of the middle cranial fossa revealed an intracranial abscess and granuloma, leading to a diagnosis of aspergillosis. The dura was reconstructed with temporalis fascia and the dead space in the skull was filled with abdominal fat. The patient was discharged 1 month later. He has survived for more than 4 years thereafter with maintenance of voriconazole using TDM.



**Fig. 3.** Gadolinium-enhanced T1-weighted axial (A) and coronal (B) image depicting a right temporal abscess (arrowheads) five months after the first surgical procedure. An enhanced lesion centered on the right optic canal also extends to the lower part of the cavernous sinus (arrow).

## DISCUSSION

Glucocorticoids and mesalazine are essential first-line treatments for ulcerative colitis and are often used in patients with mild or moderate disease.<sup>2</sup> Corticosteroids predispose patients to infections, especially when used at high doses and/or for long periods of time, or in combination with other immunosuppressive regimens.<sup>1</sup> Our patient was unable to discontinue prednisolone, but its dose was quickly reduced. However, he was taking long-term mesalazine, a multi-matrix-type anti-inflammatory drug. Known adverse effects of mesalazine include blood dyscrasias such as leucopenia and thrombocytopenia.<sup>7</sup> Mesalazine has been reported to eliminate active enzymes released from inflammatory cells such as neutrophils and macrophage.<sup>8</sup> These effects on the blood may lead to an immunocompromised state and therefore to uncommon infections such as brain abscess due to *Aspergillus*. Further, it has been reported that long-term administration of mesalazine was associated with abscess caused by central skull-base osteomyelitis.<sup>9</sup> Although our patient's blood count did not reveal any overt abnormalities, long-term mesalazine may have altered his immune system, rendering it vulnerable to brain abscess. We emphasize that this is a single case study and causation could not be proved.

The main routes of fungal CNS contamination are hematogenous dissemination from a distant primary source, mainly the lungs, and contiguous spread from an adjacent focus such as the orbit or paranasal sinuses.<sup>10</sup> Once a fungus invades the paranasal sinus mucosa, it spreads to adjacent structures by invading bone, nerve and blood vessels.<sup>11</sup> Involvement of the CNS is present in 10–15% of patients with disseminated disease,<sup>12</sup> and it may result in various pathological conditions such

as a single solid granuloma, abscess or necrotic lesion. One case report described invasive fungal aspergillosis with OAS that developed and later transformed into a temporal brain abscess after steroid administration.<sup>10</sup> Because fungi can invade the cavernous sinus via the orbital apex, OAS is considered to be an important sign heralding CNS involvement.<sup>5</sup> In our case, while there were no lung lesions, magnetic resonance imaging revealed that the lateral wall of the sphenoid sinus had disappeared (Fig. 3); that site may have been close to the first abscess. Reactivation of aspergillosis at the apex of the orbit may have extended to the outside of the sphenoid sinus via the optic canal, leading to a brain abscess.

In combination with systemic antifungal chemotherapy, radical removal of cerebral aspergilloma can be curative in *Aspergillus* brain abscess, and lobectomy is an acceptable surgical option when noneloquent areas of the brain are involved in patients with a single *Aspergillus fumigatus* abscess.<sup>13</sup> In our case, the lesion was on the right side, so it was judged that it could be resected with few complications. In addition, voriconazole is the first-line antifungal drug,<sup>14</sup> and treatment for more than half a year has been recommended for invasive fungal rhinosinusitis associated with OAS.<sup>15</sup> In our patient with severe disease, voriconazole has been administered for 4 years using TDM.

In conclusion, patients with invasive fungal rhinosinusitis and OAS should be treated postoperatively with a long-term regimen of antifungal medication. In such cases, attention should be paid to the possibility of developing a brain abscess, especially in immunosuppressed individuals. Opportunistic infections with low-pathogenicity organisms or reactivation of latent infections should always be kept in mind as differential



diagnoses in patients with ulcerative colitis who are taking glucocorticoids and mesalazine. This case emphasizes that proper surgical drainage and long-term antifungal administration are very effective in controlling infection by invasive fungal rhinosinusitis.

*Acknowledgments:* We are grateful to Dr. Yoshioka, the director of the department of neurosurgery, Tottori Prefectural Central Hospital for helpful discussions on craniotomy.

*The authors declare no conflict of interest.*

## REFERENCES

- 1 Migita K, Sasaki Y, Ishizuka N, Arai T, Kiyokawa T, Suematsu E, et al. Glucocorticoid Therapy and the Risk of Infection in Patients With Newly Diagnosed Autoimmune Disease. *Medicine (Baltimore)*. 2013;92:285-93. DOI: 10.1097/MD.0b013e3182a72299, PMID: 23982055
- 2 Team NGU. National Institute for Health and Care Excellence: Clinical Guidelines. Ulcerative colitis: management [Internet]. London: National Institute for Health and Care Excellence (UK); 2019 [cited 2020 Nov 3]. Available from: <http://www.nice.org.uk/guidance/ng130>.
- 3 Toruner M, Loftus EV Jr, Harmsen WS, Zinsmeister AR, Orenstein R, Sandborn WJ, et al. Risk factors for opportunistic infections in patients with inflammatory bowel disease. *Gastroenterology*. 2008;134:929-36. DOI: 10.1053/j.gastro.2008.01.012, PMID: 18294633
- 4 Borchard NA, Nayak JV. Orbital Apex Syndrome. *N Engl J Med*. 2018;378:e23. DOI: 10.1056/NEJMicm1703770, PMID: 29694826
- 5 Thurtell MJ, Chiu ALS, Goold LA, Akdal G, Crompton JL, Ahmed R, et al. Neuro-ophthalmology of invasive fungal sinusitis: 14 consecutive patients and a review of the literature. *Clin Exp Ophthalmol*. 2013;41:567-76. DOI: 10.1111/ceo.12055, PMID: 23279383
- 6 Siddiqui AA, Shah AA, Bashir SH. Craniocerebral aspergillosis of sinonasal origin in immunocompetent patients: clinical spectrum and outcome in 25 cases. *Neurosurgery*. 2004;55:602-13. DOI: 10.1227/01.NEU.0000134597.94269.48, PMID: 15335427
- 7 Masuda H, Takahashi Y, Nishida Y, Asai S. Comparison of the effect of mesalazine and sulfasalazine on laboratory parameters: a retrospective observational study. *Eur J Clin Pharmacol*. 2012;68:1549-55. DOI: 10.1007/s00228-012-1289-3, PMID: 22546896
- 8 Verspaget HW, Aparicio-Pagés MN, Verver S, Edelbroek PM, Hafkenscheid JCM, Crama-bohbouth GE, et al. Influence of sulphasalazine and mesalazine on cellular and biochemical oxygen metabolite production. Effect of in vivo administration and an in vitro analysis. *Scand J Gastroenterol*. 1991;26:779-86. DOI: 10.3109/00365529108998599, PMID: 1680247
- 9 Chawdhary G, Hussain S, Corbridge R. Delayed diagnosis of central skull-base osteomyelitis with abscess: case report and learning points. *Ann R Coll Surg Engl*. 2017;99:e24-7. DOI: 10.1308/rcsann.2016.0283, PMID: 27659382
- 10 Fernandes YB, Ramina R, Borges G, Queiroz LS, Maldaun MVC, Maciel JA Jr. Orbital apex syndrome due to aspergillosis: case report. *Arq Neuropsiquiatr*. 2001;59:806-8. DOI: 10.1590/S0004-282X2001000500029, PMID: 11593288
- 11 Hosseini SMS, Borghei P. Rhinocerebral mucormycosis: pathways of spread. *Eur Arch Otorhinolaryngol*. 2005;262:932-8. DOI: 10.1007/s00405-005-0919-0, PMID: 15891927
- 12 Swift AC, Denning DW. Skull base osteitis following fungal sinusitis. *J Laryngol Otol*. 1998;112:92-7. DOI: 10.1017/S0022215100140009, PMID: 9538458
- 13 Middelhof CA, Loudon WG, Muhonen MD, Xavier C, Greene CS Jr. Improved survival in central nervous system aspergillosis: a series of immunocompromised children with leukemia undergoing stereotactic resection of aspergillomas. Report of four cases. *J Neurosurg*. 2005;103(suppl):374-8. DOI: 10.3171/ped.2005.103.4.0374, PMID: 16270691
- 14 Walsh TJ, Anaissie EJ, Denning DW, Herbrecht R, Kontoyannis DP, Marr KA, et al.; Infectious Diseases Society of America. Treatment of aspergillosis: clinical practice guidelines of the Infectious Diseases Society of America. *Clin Infect Dis*. 2008;46:327-60. DOI: 10.1086/525258, PMID: 18177225
- 15 Arakawa H, Suto C, Notani H, Ishida T, Abe K, Ookubo Y. Selection of the antifungal agent decides prognosis of invasive aspergillosis: case report of a successful outcome with voriconazole. *Int Ophthalmol*. 2014;34:85-9. DOI: 10.1007/s10792-013-9730-x, PMID: 23397120