

## Investigation of the Utility and Safety of Dynamic Computed Tomography with Vasodilators

Jun Watanabe,\* Kanenori Endo,\* Yasutaka Tanaka,† Keisuke Goto,\* Shoichi Urushibara,\* Tomohiro Osaki,\* Shigeru Tatebe,\* Seiichi Nakamura,\* Yasuaki Hirooka\* and Masahide Ikeguchi\*

\*Department of Surgery, Tottori Prefectural Central Hospital, Tottori 680-0901, Japan, and †Department of Radiology, Tottori Prefectural Central Hospital, Tottori 680-0901, Japan

### ABSTRACT

**Background** Dynamic computed tomography (CT) angiography is useful for evaluating of hepatic vascularity. Although vasodilators increase hepatic blood flow, the utility of dynamic CT with vasodilators is unclear. Here we investigated the utility and safety of dynamic CT with vasodilators.

**Methods** A prospective case-control radiographic evaluation using abdominal dynamic CT with and without vasodilator was performed at a single center between October 2015 and September 2016. We compared the CT values in Hounsfield units of the aorta; celiac artery; and common, right, and left hepatic arteries in the arterial phase and the main trunk; right and left branches of the portal vein; and right, middle, and left hepatic veins in the portal phase with and without vasodilators. The region of interest was set in each element of the liver vasculature. Four radiological technologists independently and visually compared the scores of the portal vein (P-score) and hepatic vein (V-score) on a 5-point scale with and without vasodilators.

**Results** The CT values of arteries and veins using vasodilators were significantly higher than those without vasodilators. With and without vasodilators, the P-scores were  $3.1 \pm 1.2$  and  $4.0 \pm 1.1$  ( $P < 0.05$ ) and the V-scores were  $3.3 \pm 1.4$  and  $4.3 \pm 1.0$  ( $P < 0.05$ ). Only one patient with vasodilator use had transient hypotension and recovered immediately without medication.

**Conclusion** Dynamic CT with vasodilators can provides better visualization of vascular structures.

**Key words** abdomen; computed tomography; liver; vasodilator agents

Dynamic contrast-enhanced computed tomography (CE-CT) is useful for evaluating hepatic vascularity.<sup>1, 2</sup> Hepatectomy is the most effective treatment for hepatocellular carcinoma and the number of laparoscopic approaches to liver resection has increased in recent years.<sup>3</sup> Detailed knowledge of the liver vasculature is important to ensure a safe and successful liver surgery.<sup>4, 5</sup>

Vasodilators, such, as nitroglycerin spray are routinely used to maximally dilate the epicardial coronary arteries during coronary angiography.<sup>6</sup> Although vasodilator use increases hepatic blood flow, the utility of dynamic CE-CT with vasodilator is unclear.<sup>7</sup>

Thus, here we aimed to examine the utility of dynamic CE-CT with vasodilator.

### MATERIALS AND METHODS

#### Study population

This was a prospective case-control study of patients undergoing dynamic CE-CT with or without vasodilator use between October 2015 and September 2016 at the Department of Surgery of Tottori Prefectural Central Hospital. Patients undergoing abdominal dynamic CE-CT for any reason were included and those in whom use of vasodilators was contraindicated were excluded from the study. Patients who had consented to the use of vasodilators were randomly assigned to the intervention and control groups. A total of 62 patients (25 men, 37 women) aged 38–87 years were analyzed. This study was approved by the ethics board of Tottori Prefectural Central Hospital (approval number: 16-10). Written informed consent was obtained from each patient.

#### CT protocols

Sixty patients underwent scanning at 120kV with a multidetector CT instrument (Aquilion ONE; Cannon Medical Systems, Tokyo, Japan) with breath holding at inspiration; the contrast dose was iodine 600 mg/kg. Three minutes before the initiation of contrast injection, sublingual nitroglycerin was administered by a nurse, who sprayed one puff from a spray device (0.3 mg/puff; Myocor spray; Toa Eiyō Company Limited, Tokyo, Japan). After obtaining a non-contrast CT scan, nonionic

Corresponding author: Jun Watanabe, MD

m06105jw@jjichi.ac.jp

Received 2019 November 21

Accepted 2020 January 17

Online published 2020 January 24

Abbreviations: CE-CT, contrast-enhanced computed tomography; HU, Hounsfield units; SD, standard deviation

Score	<u>Right posterior inferior segmental branch of the portal vein to S6</u>
5	The fifth branches are clearly visualized
4	The fifth branches are barely visualized
3	The fourth branches are clearly visualized
2	The fourth branches are barely visualized
1	The third branches are visualized
Score	<u>Right hepatic vein</u>
5	The fourth branches are clearly visualized
4	The fourth branches are barely visualized
3	The third branches are clearly visualized
2	The third branches are barely visualized
1	The second branches are visualized

**Fig. 1.** Visual evaluation of CT imaging. All CT images were reviewed and graded by four radiologists using a 5-point scale for the visualization of vascular structures.

contrast material [iohexol 240 mgI/mL, Omnipaque 240 (Daiichi Sankyo Company Limited, Tokyo, Japan) for patients weighing < 45 kg; iopamidol 300 mgI/mL, Oypalomin (Fuji Pharma Company Limited, Tokyo, Japan) for patients weighing 45–52 kg; iopamidol 370 mgI/mL, Iopamiron 370 (Bayer Healthcare, Osaka, Japan) for patients weighing 53–65 kg; and iomeprol 350 mgI/mL, Iomeron 350 (Daiichi Sankyo Company Limited) for patients weighing ≥ 66 kg] was administered at a flow rate of 3.0–5.0 mL/s using an automated power injector (Dual Shot GX7; Nemoto Kyorindo, Tokyo, Japan) following a three-phase dynamic CT scanning during the hepatic arterial, portal, and venous phases. A bolus-tracking method was used to determine the scanning start time in each phase after the contrast material injection. The anatomical level for monitoring was set in the celiac artery that branched from the descending aorta. The trigger threshold was set at 200 Hounsfield units (HU). Dynamic image acquisition consisted of three sequences: the arterial phase initiated 7 seconds after the trigger, the portal phase acquired 14 seconds after arterial phase, and the hepatic venous phase that was scanned 3 minutes after a bolus injection of the contrast agent.

The parameters were detector configuration (80 × 0.5 mm) (detector collimation), slice thickness (5 mm), section interval (5 mm), and gantry rotation time (0.5 s), and 120 kV using an automatic exposure system with a reference standard deviation (SD) of 10.

### CT values

The scanned images were processed using a ZIOSTATION 2 workstation (Amin Company Limited, Tokyo, Japan).

A circular region of interest of an area equivalent to approximately 70% of the diameter of each vascularity element was selected in the CT cross section and the CT values measured. We compared the CT values in HU of the arteries in the arterial phase and the portal veins and the hepatic veins in the portal phase with versus without vasodilator use. We evaluated the aorta, celiac artery, common hepatic artery, right hepatic artery, and left hepatic artery in the arterial phase as well as the main trunk, right and left branches of the portal vein, and right, middle, and left hepatic veins in the portal phase.

### Visual evaluation of CT imaging

The vascular structures were visually evaluated on the CT cross section. All the CT images were independently reviewed and graded by four radiological technologists with 7, 9, 12, and 17 years of experience using a 5-point scale for visualization of the vascular structures [portal vein (P-score) and hepatic vein score (V-score)] (Fig. 1). The P-scores and V-scores were computed by calculating the average of the scores evaluated by the four radiological technologists. The 5-point scoring of the portal vein was as follows: 5 (excellent) = fifth branches of the portal vein are clearly visualized, sufficient information; 4 (good) = fifth branches of the portal vein are visualized, but unclear, useful information; 3 (fair) = fourth branches of the portal vein are clearly visualized but fifth branches of the portal vein are difficult to identify, acceptable information; 2 (unacceptable) = fourth branches of the portal vein are visualized but unclear, inadequate information; and 1 (poor) = third branches are visualized, but fourth branches of the portal vein are difficult to identify, poor information. The 5-point

**Table 1. Characteristics of all patients**

<sup>a</sup>	Vasodilator group ( <i>n</i> = 25)	Control group ( <i>n</i> = 37)	<i>P</i> <sup>b</sup>
Age, year	63.9 ± 11.8	66.2 ± 13.1	0.48
Male, <i>n</i> (%)	13 (52)	22 (59)	0.47
Body weight, kg	54.1 ± 11.8	54.8 ± 12.3	0.84
Background disease, <i>n</i> (%)			0.011
Hepatobiliary tract diseases	13 (52)	25 (68)	
Pancreatic diseases	8 (32)	8 (22)	
Gallbladder diseases	2 (8)	2 (5)	
Other diseases	2 (8)	2 (5)	

<sup>a</sup> Data are shown as mean ± standard deviation for quantitative data and as percentage of patients for qualitative data.

<sup>b</sup> *P* values were calculated using the Mann-Whitney *U* test for variance and the chi-square test for variables.

scoring of the hepatic vein was as follows: 5 (excellent) = fourth branches of the hepatic vein are clearly visualized, sufficient information; 4 (good) = fourth branches of the hepatic vein are visualized, but unclear, useful information; 3 (fair) = third branches of the hepatic vein are clearly visualized but fourth branches of the hepatic vein are difficult to identify, acceptable information; 2 (unacceptable) = third branches of the hepatic vein are visualized but unclear, inadequate information; and 1 (poor) = second branches are visualized, but third branches of the hepatic vein are difficult to identify, poor information.

### Statistics

Continuous variables, including age and body weight, are expressed as mean and SD. Categorical variables, including sex, are expressed as numbers and percentages. Summary statistics were used to compare the characteristics of patients undergoing dynamic CE-CT with versus without vasodilator use with the Mann-Whitney *U* test for continuous variables and chi squared test for categorical variables. We used the chi squared tests to compare the CT values of the arteries in the arterial phase, the veins in the portal phase, and visual evaluation of CT imaging between patients undergoing dynamic CE-CT with versus without vasodilator use. Values of *P* < 0.05 were considered significant. We performed sensitivity analysis excluding patients with cirrhosis of the liver. All statistical analyses were performed using SPSS version 25.0 (IBM, Armonk, NY). The patients' data were safely stored in a locked safe, anonymized and analyzed on an encrypted computer without an internet connection.

### RESULTS

The characteristics of all the patients included in this study are shown in Table 1. There were no significant differences in age, sex, or body weight between patients undergoing dynamic CE-CT with versus without a vasodilator. In the vasodilator and control groups, the mean ages were 63.9 ± 11.8 and 66.2 ± 13.1 (*P* = 0.48) and mean body weights were 54.1 ± 11.8 kg and 54.8 ± 12.3 kg (*P* = 0.84), respectively. The vasodilator and control groups included 52% and 59% men, respectively (*P* = 0.47). Patients under treatment with vasodilators had a lower evidence of liver disease than those who were not on vasodilators (*P* = 0.011). Five patients on vasodilators had cirrhosis of the liver, which was absent in those who were not using vasodilators.

Figure 2 compares the CT values in HU of the arteries in the arterial phase. The CT values in HU in patients undergoing dynamic CE-CT in the vasodilator and control groups were 416 ± 76.5 and 367 ± 62.7 in the aorta (*P* = 0.003), 425 ± 80.4 and 371 ± 59.4 in the celiac artery (*P* = 0.001), 416 ± 79.1 and 355 ± 60.7 in the common hepatic artery (*P* < 0.001), 376 ± 88.3 and 259 ± 62.5 in the right hepatic artery (*P* < 0.001), and 342 ± 71.3 and 241 ± 47.6 in the left hepatic artery (*P* < 0.001), respectively.

Figure 3 compares the CT values of the portal veins and the hepatic veins in the portal phase. The CT values in the vasodilator and control group were 224 ± 31.8 and 206 ± 28.1 in the portal vein (*P* = 0.02), 217 ± 27.7 and 202 ± 30.8 in the right branch of the portal vein (*P* = 0.04), and 223 ± 29.6 and 206 ± 31.0 in the left branch of the portal vein (*P* = 0.04), respectively. In the vasodilator and control group, the CT values were 229 ± 28.3 and 189 ± 26.2 in the hepatic vein (*P* < 0.001), and 223 ± 38.8 and 194 ± 35.4 in the right hepatic vein (*P* =

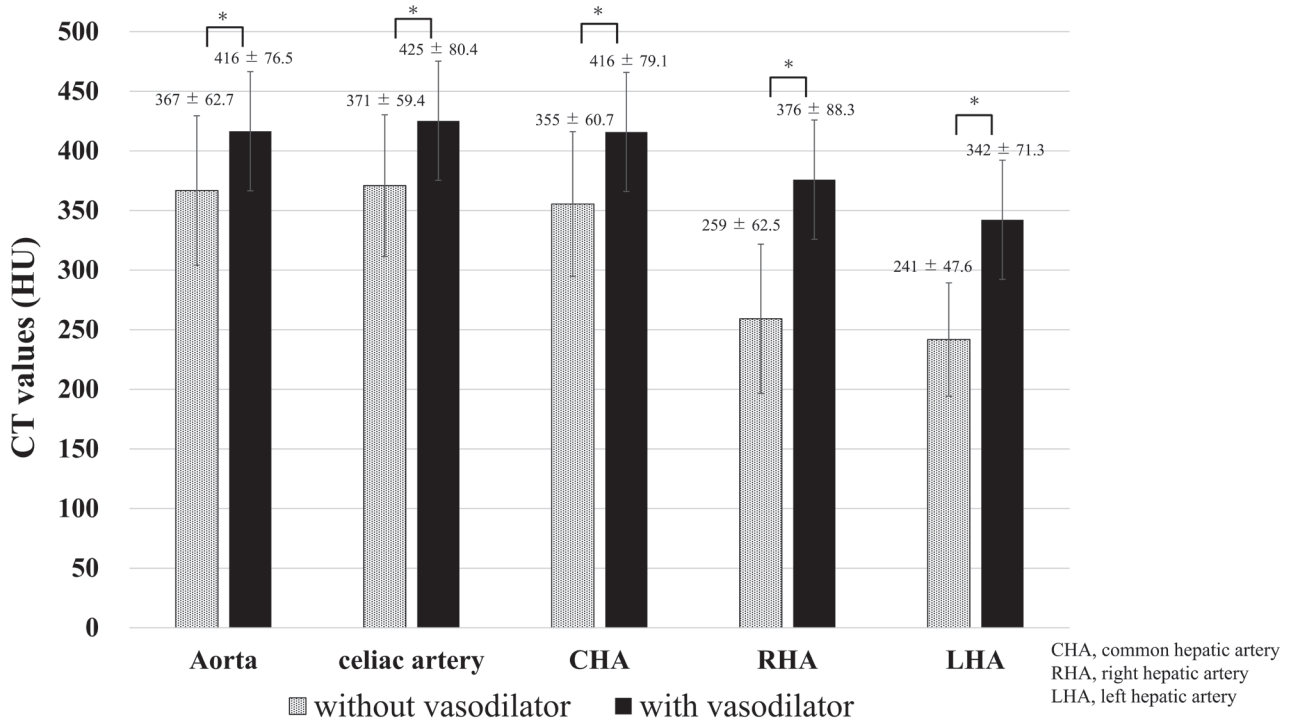


Fig. 2. CT values of the arteries in the arterial phase. \* $P < 0.05$

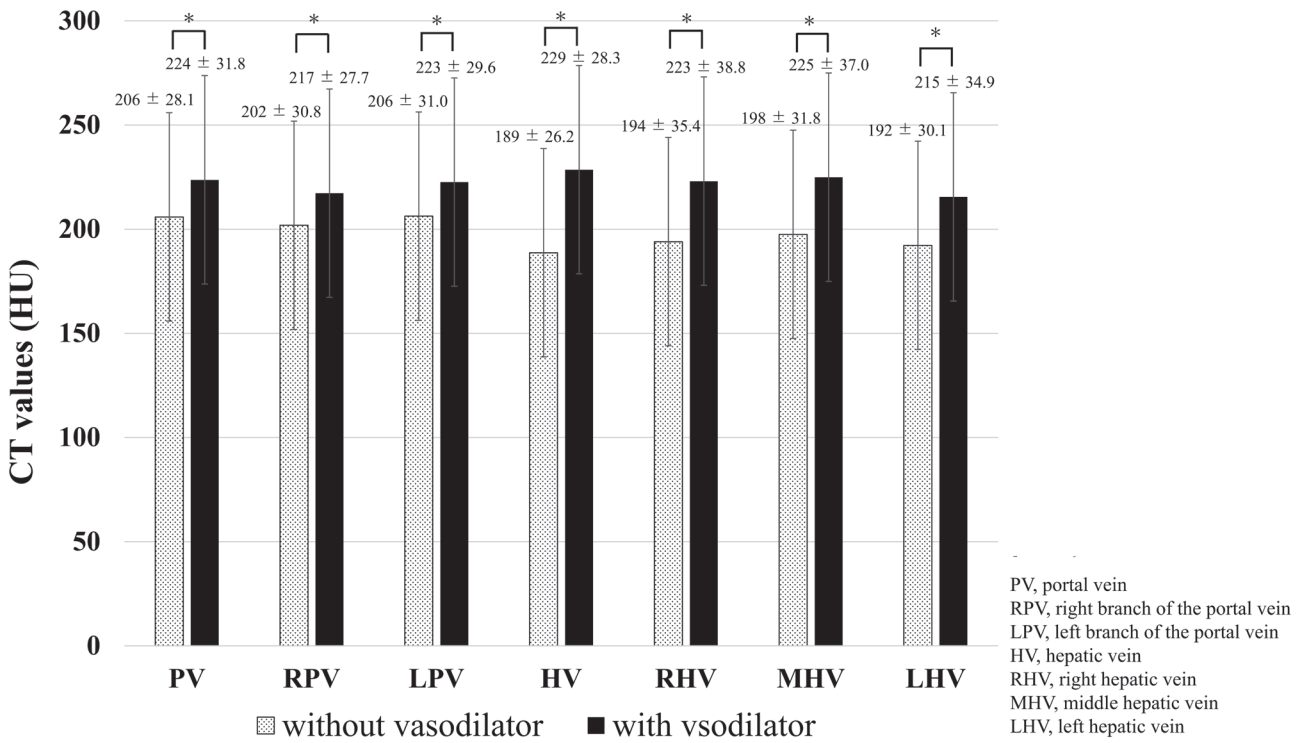


Fig. 3. CT values of the veins in the portal phase. \* $P < 0.05$

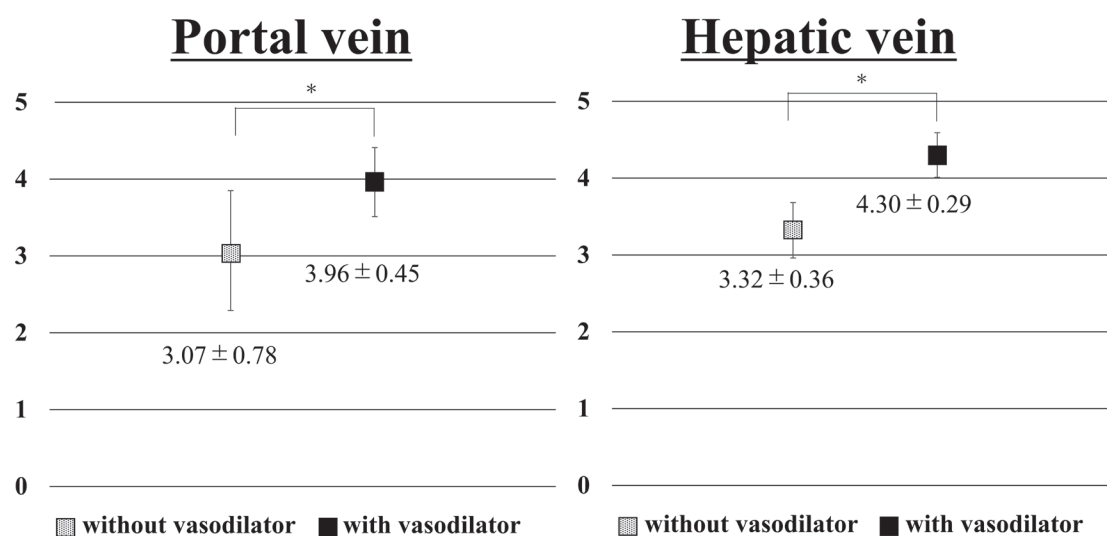


Fig. 4. Visual evaluation of CT imaging. \* $P < 0.05$

**Table 2. Characteristics of patients excluding those with cirrhosis of the liver in the control group**

<sup>a</sup>	Vasodilator group ( <i>n</i> = 25)	Control group ( <i>n</i> = 32)	<i>P</i> <sup>b</sup>
Age, year	63.9 ± 11.8	66.4 ± 13.9	0.47
Male, <i>n</i> (%)	13 (52)	17 (53)	0.82
Body weight, kg	54.1 ± 11.8	52.3 ± 10.7	0.62
Background disease, <i>n</i> (%)			0.16
Hepatobiliary tract diseases	13 (52)	20 (63)	
Pancreatic diseases	8 (32)	8 (25)	
Gallbladder diseases	2 (8)	2 (6)	
Other diseases	2 (8)	2 (6)	

<sup>a</sup> Data are shown as mean ± standard deviation for quantitative data and as percentage of patients for qualitative data.

<sup>b</sup> *P* values were calculated using the Mann-Whitney *U* test for variance and the chi-square test for variables.

0.003),  $225 \pm 37.0$  and  $198 \pm 31.8$  in the middle hepatic vein ( $P = 0.002$ ), and  $215 \pm 34.9$  and  $192 \pm 30.1$  in the left hepatic vein ( $P = 0.006$ ), respectively.

Figure 4 compares the visual evaluation of CT imaging in the portal vein and the hepatic vein. In the vasodilator and control groups, the P-scores were  $4.0 \pm 0.5$  and  $3.1 \pm 0.8$  ( $P < 0.05$ ), respectively. The V-scores in the vasodilator and control groups were  $4.3 \pm 0.3$  and  $3.3 \pm 0.4$  ( $P < 0.05$ ), respectively.

In the vasodilator group, there was one case of transient hypotension that immediately recovered without treatment. In the control group, no adverse events occurred.

In the sensitivity analysis, after excluding patients with cirrhosis of the liver in the control group, there was no significant difference in the background disease

between patients with and without treatment with vasodilators ( $P = 0.16$ ). The results of the sensitivity analyses thus performed were consistent with the primary findings. The results of the aforementioned analyses are shown in Table 2 and Figs. 5, 6 and 7.

## DISCUSSION

In this study, dynamic CE-CT with vasodilator use yielded statistically better visualization of the hepatic vascular structures than the standard dynamic CE-CT. These results of the present study are important because the utility and safety of dynamic CE-CT with vasodilator use was not proven previously.

Several dynamic CE-CT protocols have been proposed to clarify the hepatic vascular structure.<sup>8–11</sup> A retrospective study showed that CT with a combined

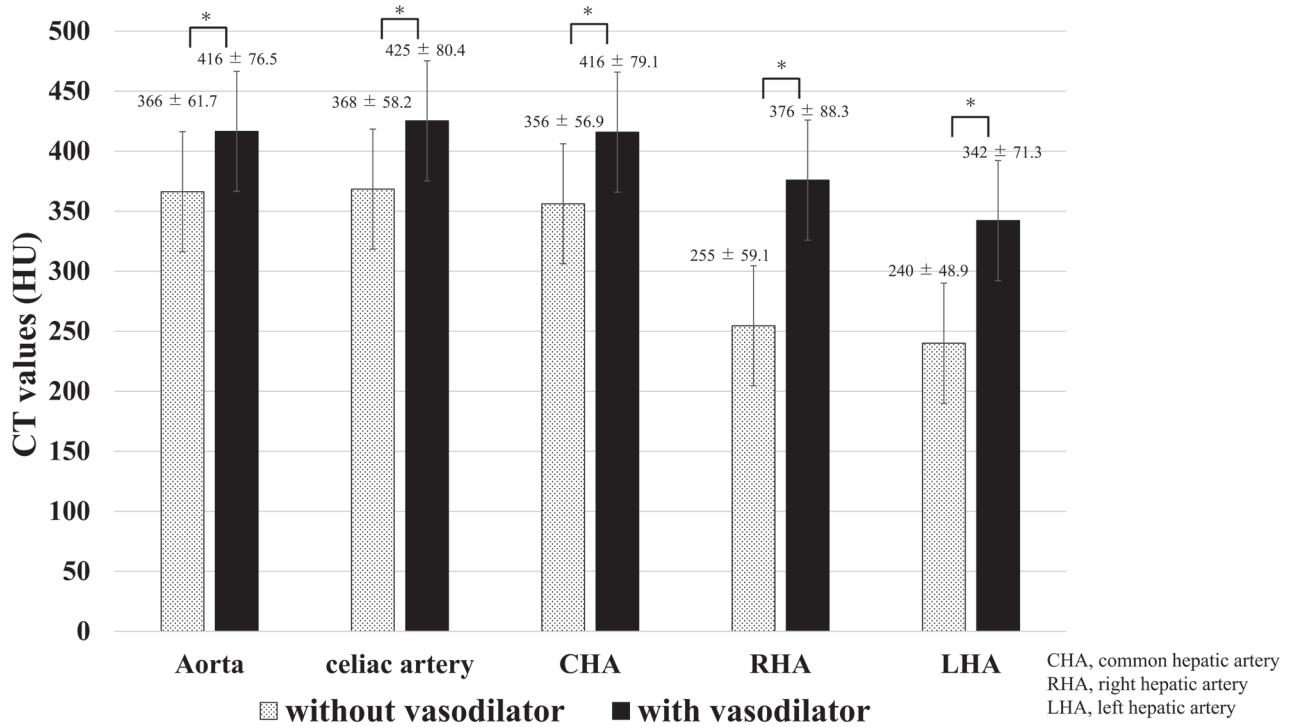


Fig. 5. CT values of the arteries in the arterial phase after excluding patients with cirrhosis of the liver. \* $P < 0.05$

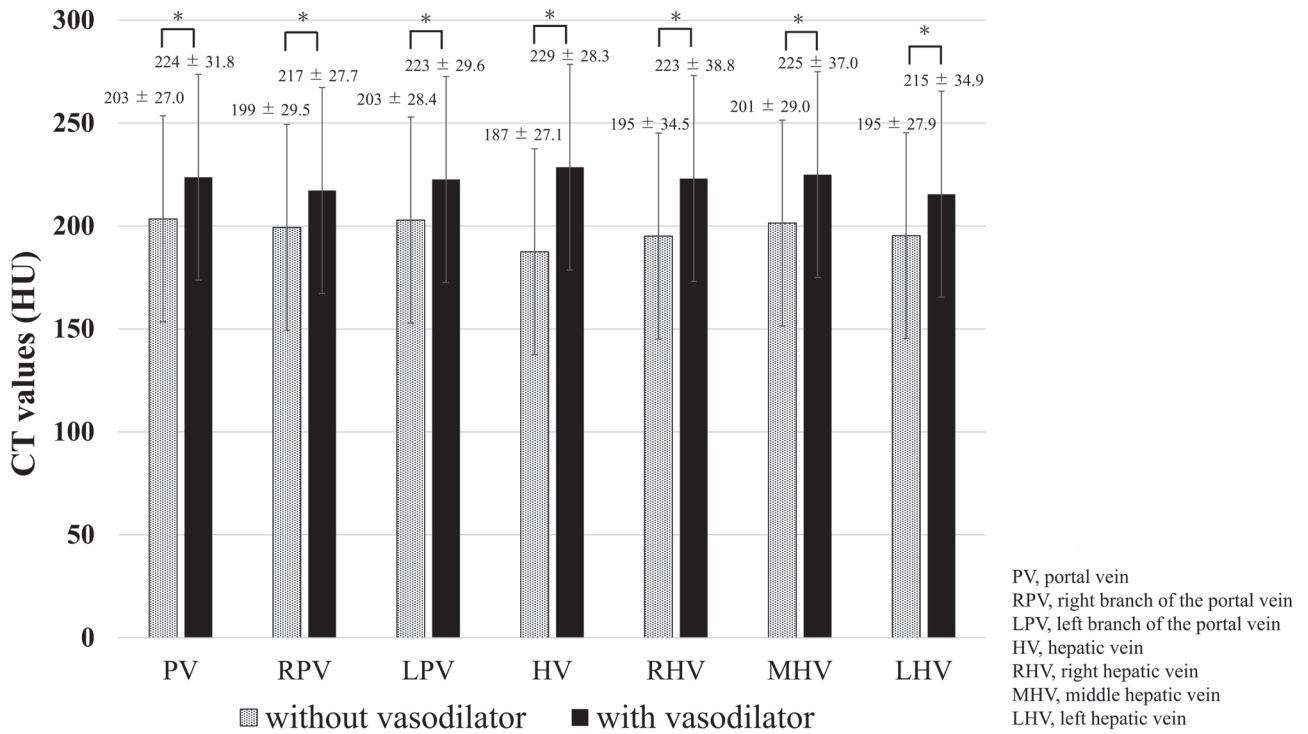


Fig. 6. CT values of the veins in the portal phase after excluding patients with cirrhosis of the liver. \* $P < 0.05$

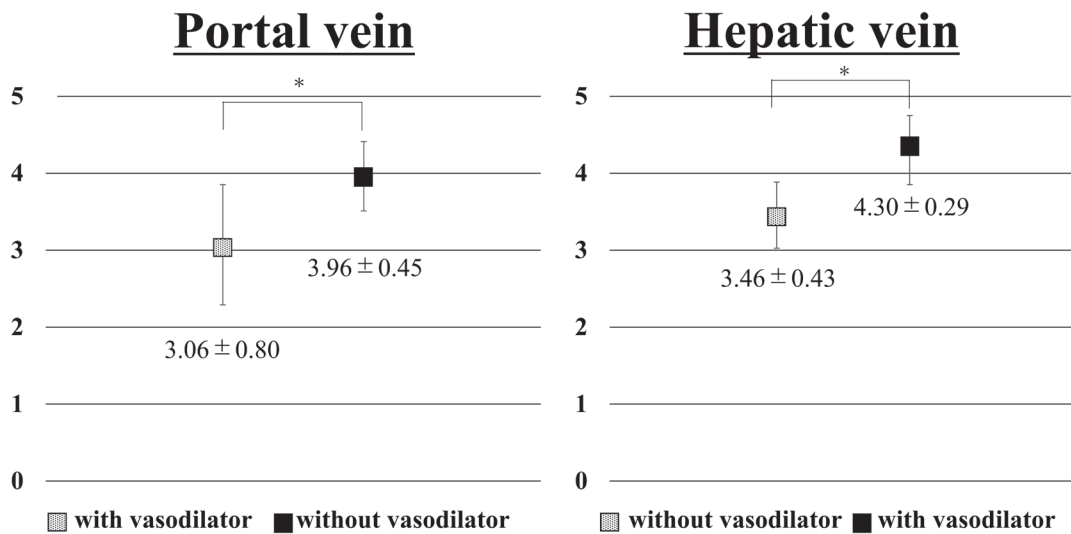


Fig. 7. Visual evaluation of CT imaging after excluding patients with cirrhosis of the liver. \* $P < 0.05$

technique of lower tube voltage and iterative reconstruction can provide sufficiently preoperative information for liver transplantation.<sup>8</sup> A previous study showed that a liver CT protocol with later arterial phase, faster infusion rate, and weight-based dosing of intravenous contrast significantly improved liver enhancement and iodine concentrations in patients with cirrhosis.<sup>9</sup> Although CT values in HU of the arteries were increased by changing the injection protocol, contrast medium amount, or device, visual evaluations of vascular construction did not improve at CT values above a certain level.<sup>12</sup> We demonstrated here that the CT values of the arteries, and the portal veins and the hepatic veins in the vasodilator group were higher than those in the control group and that dynamic CE-CT with vasodilator use clearly visualized vascular structures.

In order to perform liver surgeries safely, it is essential to understand the complexities of the liver vasculature.<sup>3, 4</sup> Particularly, in preoperative evaluation, it is crucial to understand the liver vasculature including the portal vein and hepatic vein in order to accurately identify the liver segments.<sup>6</sup> It was demonstrated that dynamic CE-CT with the use of vasodilators provided a clearer visualization of the hepatic vasculature including the portal and hepatic veins.

Although the mechanism of clear visualization of vascular structures with vasodilator use remains to be elucidated, the previous study reported that when a blood vessel is expanded with a vasodilator, the peripheral vascular resistance is reduced and the blood volume is increased.<sup>13</sup> Therefore, even if the blood concentration of the contrast agent remains the same, the intravascular volume increases, thereby improving the clinician's

ability to detect the vascular structure.<sup>14</sup>

A previous systematic review reported that the side effects of sublingual nitroglycerin administered during CT angiography were mild and were alleviated without treatment.<sup>6</sup> The present study showed that there was transient hypotension in patients that was associated with the use of vasodilators, which but immediately improved without medical intervention. Use of nitroglycerin is contraindicated in patients on phosphodiesterase inhibitors for the treatment of erectile dysfunction or pulmonary hypertension.<sup>15</sup> In this study, none of the patients were on phosphodiesterase inhibitors.

This study has several limitations. First, the number of cases was small, and the patients were recruited from a single center. In addition, patients with and without treatment with vasodilators are two different cohorts. However, there was no significant difference between the groups but for the presence of background disease. The results of the sensitivity analyses that excluded participants with cirrhosis of the liver in order to match the background disease were consistent with the primary findings. Second, it remains unclear whether dynamic CE-CT with vasodilator use is useful for making the diagnosis of liver disease. However, dynamic CE-CT with vasodilator use enables the clear visualization of liver vascular structures. Third, although the use of vasodilators may shift the timing of imaging of the arterial and portal phase, the CT values in HU of the hepatic arteries and veins and the portal veins were high. Fourth, the weight-based dosing of the various contrast agents accounted for non-uniformity in vascular assessment. However, the contrast agents were administered using a body-weight based protocol because normal

parenchymal enhancement was regulated primarily by the total amount of iodine injected per unit body weight.<sup>16</sup> Finally, the current mainstream for enhancing the visualization of vascularity in CT scans include low tube voltage and low-dose contrast agent scanning protocols that reduce radiation and iodine intake. However, dynamic CT with the use of vasodilators may be useful.<sup>17</sup>

In conclusion, dynamic CE-CT with vasodilator use provides better visualization of hepatic vascular structures than standard dynamic CE-CT. These findings imply that dynamic CE-CT with vasodilator use may be sufficiently simple, safe, and informative for a preoperative CT evaluation of liver resection. Further investigations are needed to elucidate the utility of dynamic CE-CT with vasodilator use for preoperative CT evaluations of liver resection.

*Acknowledgments:* The authors thank Mr. Tadamas Ueyama, Mr. Makoto Koyama, Mr. Yutaro Okamoto, and the radiological technologists and staff members of Tottori Prefectural Central Hospital.

*The authors declare no conflicts of interest.*

## REFERENCES

- Ueda K, Matsui O, Kawamori Y, Nakanuma Y, Kadoya M, Yoshikawa J, et al. Hypervascular hepatocellular carcinoma: evaluation of hemodynamics with dynamic CT during hepatic arteriography. *Radiology*. 1998;206:161-6. DOI: 10.1148/radiology.206.1.9423667, PMID: 9423667
- Kitao A, Zen Y, Matsui O, Gabata T, Nakanuma Y. Hepatocarcinogenesis: multistep changes of drainage vessels at CT during arterial portography and hepatic arteriography--radiologic-pathologic correlation. *Radiology*. 2009;252:605-14. DOI: 10.1148/radiol.2522081414, PMID: 19703890
- Ciria R, Gomez-Luque I, Ocaña S, Cipriani F, Halls M, Briceño J, et al. A systematic review and meta-analysis comparing the short- and long-term outcomes for laparoscopic and open liver resections for hepatocellular carcinoma: updated results from the European Guidelines Meeting on Laparoscopic Liver Surgery, Southampton, UK, 2017. *Ann Surg Oncol*. 2019;26:252-63. DOI: 10.1245/s10434-018-6926-3, PMID: 30390167
- European Association for the Study of the Liver. EASL Clinical Practice Guidelines: management of hepatocellular carcinoma. *J Hepatol*. 2018;69:182-236. DOI: 10.1016/j.jhep.2018.03.019, PMID: 29628281
- Omata M, Cheng AL, Kokudo N, Kudo M, Lee JM, Jia J, et al. Asia-Pacific clinical practice guidelines on the management of hepatocellular carcinoma: a 2017 update. *Hepatol Int*. 2017;11:317-70. DOI: 10.1007/s12072-017-9799-9, PMID: 28620797
- Takx RAP, Suchá D, Park J, Leiner T, Hoffmann U. Sublingual nitroglycerin administration in coronary computed tomography angiography: a systematic review. *Eur Radiol*. 2015;25:3536-42. DOI: 10.1007/s00330-015-3791-3, PMID: 25994194
- Hayashi S, Dono K, Shimizu J, Murakami T, Takamura M, Kim T, et al. New measurement of hepatic blood flow by xenon CT system: an animal study with PGE1. *J Surg Res*. 2005;129:24-30. DOI: 10.1016/j.jss.2005.01.027, PMID: 16243046
- Yoshida M, Utsunomiya D, Kidoh M, Yuki H, Oda S, Shiraishi S, et al. CT evaluation of living liver donor : Can 100-kVp plus iterative reconstruction protocol provide accurate liver volume and vascular anatomy for liver transplantation with reduced radiation and contrast dose? *Medicine (Baltimore)*. 2017;96:e6973. DOI: 10.1097/MD.0000000000006973, PMID: 28591031
- Eddy K, Costa AF. Assessment of cirrhotic liver enhancement with multiphasic computed tomography using a faster injection rate, late arterial phase, and weight-based contrast dosing. *Can Assoc Radiol J*. 2017;68:371-8. DOI: 10.1016/j.carj.2017.01.001, PMID: 28720415
- Honda K, Oda S, Katahira K, Kajihara H, Morishita S, Honbori M, et al. Three-dimensional computed tomographic angiography of the liver for planning hepatic surgery: effect of low tube voltage and the iterative reconstruction algorithm on image quality. *J Comput Assist Tomogr*. 2014;38:131-6. DOI: 10.1097/RCT.0b013e3182a9a518, PMID: 24424561
- Matsuda I, Hanaoka S, Akahane M, Sato J, Komatsu S, Inoh S, et al. Adaptive statistical iterative reconstruction for volume-rendered computed tomography portovenography: improvement of image quality. *Jpn J Radiol*. 2010;28:700-6. DOI: 10.1007/s11604-010-0490-5, PMID: 21113757
- Yuta A, Kiminori T, Minoru T, Osamu I, Masahiro S, Minoru K, et al. Surgical approach in borderline resectable pancreatic cancer with preoperative 3D-CT computer assisted surgery planning. *Tan to Shui*. 2013;34:87-95. Japanese.
- Groszmann RJ, Kravetz D, Bosch J, Glickman M, Bruix J, Bredfeldt J, et al. Nitroglycerin improves the hemodynamic response to vasopressin in portal hypertension. *Hepatology*. 1982;2:757-62. DOI: 10.1002/hep.1840020602, PMID: 6815044
- Pannen BHJ, Bauer M. Differential regulation of hepatic arterial and portal venous vascular resistance by nitric oxide and carbon monoxide in rats. *Life Sci*. 1998;62:2025-33. DOI: 10.1016/S0024-3205(98)00174-X, PMID: 9627101
- Drugs and Lactation Database (LactMed) [Internet]. National Library of Medicine (US); Bethesda (MD): 2006. Nitroglycerin. PMID: 30000576
- Seifarth H, Puesken M, Kalafut JF, Wienbeck S, Wessling J, Maintz D, et al. Introduction of an individually optimized protocol for the injection of contrast medium for coronary CT angiography. *Eur Radiol*. 2009;19:2373-82. DOI: 10.1007/s00330-009-1421-7, PMID: 19424699
- Zhang X, Li S, Liu W, Huang N, Li J, Cheng L, et al. Double-low protocol for hepatic dynamic CT scan : Effect of low tube voltage and low-dose iodine contrast agent on image quality. *Medicine (Baltimore)*. 2016;95:e4004. DOI: 10.1097/MD.0000000000004004, PMID: 27368012