

## A Case of Skull Base Chondrosarcoma with Intraoperative Trigemino-Cardiac Reflex

Hiroaki Yazama,\* Kensaku Hasegawa,† Masamichi Kurosaki,‡ Yasuomi Kunimoto,§ Tasuku Watanabe,\* Kazunori Fujiwara\* and Hiromi Takeuchi\*

\*Division of Otolaryngology, Head and Neck Surgery, Department of Sensory and Motor Organs, School of Medicine, Faculty of Medicine, Tottori University, Yonago 683-8503, Japan, †Nippon Medical School Chiba Hokusoh Hospital, Inzai 270-1694, Japan, ‡Institute of Neurological Sciences, Department of Neurosurgery, Faculty of Medicine, Tottori University, Yonago 683-8503, Japan, and §Kunimoto ENT clinic, Yonago 683-0805, Japan

### ABSTRACT

A 75-year-old female patient presented with a suspected recurrence of a clival chordoma. The tumor was resected using the infratemporal fossa type B and anterior petrosal approach with the help of a neurosurgeon. During cauterization of the trigeminal nerve, the patient developed cardiac arrest for approximately 10 seconds because of the trigemino-cardiac reflex (TCR). After several sternal compressions, there was return of spontaneous circulation. The operation was resumed after the circulatory dynamics stabilized. Subsequently, the surgery was completed with partial resection of the tumor without the recurrence of cardiac arrest. The pathological diagnosis was chondrosarcoma, and postoperative treatment with radiotherapy was started. Stimulation of the sensory branches of the trigeminal nerve induces TCR. There are reports of TCR developing in approximately 10% of skull base surgery cases in the absence of atropine administration. We report a rare case of TCR during the surgical procedure for the treatment of a skull base chondrosarcoma.

**Key words** chondrosarcoma; infratemporal fossa; trigemino-cardiac reflex

The trigemino-cardiac reflex (TCR) is caused by central or peripheral stimulation of the sensory branches of the trigeminal nerve. It is characterized by sudden bradycardia, cardiac arrest, hypotension, respiratory arrest, and intestinal hypermobility. It has been reported mainly in surgery performed on the skull base and brainstem lesions. In the present study, we experienced a case of cardiac arrest of approximately 10 seconds because of TCR during tumor resection using the infratemporal fossa

type B approach (IFTB) and anterior petrosal approach. We describe the prognosis and prevention of TCR in skull base surgery with a review of the literature.

### PATIENT REPORT

The patient was a 75-year-old female with no significant medical comorbidities. Two and a half years before her visit to our department, she developed a right abducent nerve palsy and was subsequently diagnosed with a skull base tumor. The neurosurgeon performed a tumor resection using the middle fossa and anterior petrosal approach. The intraoperative findings revealed a chordoma-like tumor with no obvious malignant findings on histopathology. She was carefully managed and followed up as a case of chordoma, with the possibility of chondrosarcoma. Subsequently, the right abducent nerve palsy improved. However, the previous symptom recurred, this time accompanied by double vision, dizziness, and paresthesia of the right side of the face. The patient was admitted to the hospital for reoperation and was referred to our department for intraoperative co-management.

The oblique view of the cranial magnetic resonance image showed irregularities; a T1-weighted image low, and T2-weighted image high intensity, extending from the caudal to the pyramidal region of the brainstem (Fig. 1). Due to the position of the mass, damage to the trigeminal and abducent nerves was anticipated. However, the patient's hearing was equal bilaterally, the caloric test was normal, and no facial nerve palsy was observed. Therefore, it was assumed that the lower cranial nerves were not affected. There were no other underlying diseases or physical findings that would indicate potential complications during anesthesia. Based on the results of these examinations, it was necessary to use the previous operation site and to approach the right side of the oblique caudal to the pyramid and anterior part of the brainstem. Hence, tumor resection with an anterior petrosal approach and IFTB was planned.

The surgery was performed following a typical procedure, and the third branch of the trigeminal nerve

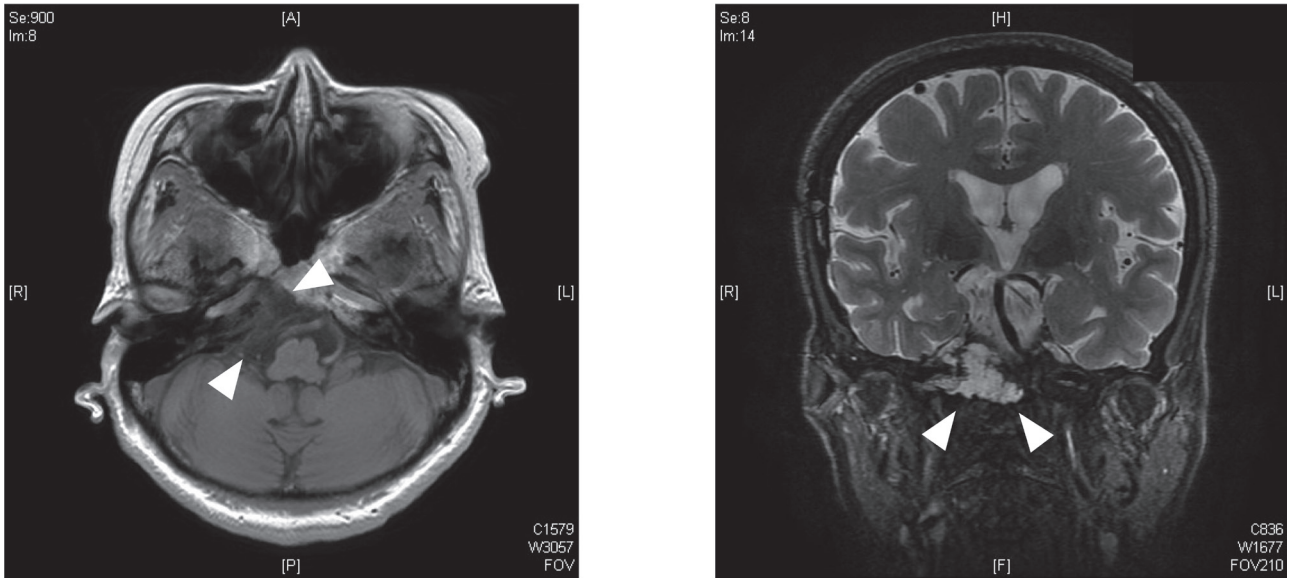
Corresponding author: Hiroaki Yazama, MD, PhD  
h-yazama@tottori-u.ac.jp

Received 2020 September 30

Accepted 2020 October 15

Online published 2020 November 24

Abbreviations: BIS index, Bispectral index; IFTB, infratemporal fossa type B approach; TCR, trigemino-cardiac reflex; VMAT, Volumetric Modulated Arc Therapy



**Fig. 1.** Preoperative magnetic resonance images. Arrowheads indicate tumor position.

was exposed. When the third branch of the trigeminal nerve was cut, the patient went into cardiac arrest for 10 seconds. Immediately, the anesthesiologist was able to restore sinus rhythm and circulation by administering atropine and performing chest compressions. Oxygen saturation was maintained at 100% and CO<sub>2</sub> concentration was appropriately controlled at 35–40 mmHg. Further, intraoperative anesthesia depth was appropriate at 40–50 BIS index, and circulation was stable; hence, we concluded that the TCR had occurred. The surgery was then completed uneventfully. Histopathology of the specimen revealed chondrosarcoma, and postoperative radiation therapy (VMAT 60Gy/30Fr) was started. Seven years postoperatively, the patient remains on regular outpatient follow-up and there is no apparent increase in tumor size.

## DISCUSSION

Histologically, chondrosarcoma is derived from primitive mesenchymal cells and embryonic remnants of cartilage membranes. This neoplasm can occur in any bone in the body; however, it rarely develops at the base of the skull. The global incidence is estimated to be 0.03 per 100,000 of the general population. The reported incidence of chondrosarcoma at the skull base is approximately 5% of all chondrosarcoma patients. In general, complete resection is considered a curative treatment. However, complete removal of the tumor in the skull base is difficult due to the presence of adjacent vital organs, and there is no standardized treatment for this disease. Sbaihat et al.<sup>1</sup> evaluated 13 cases treated

in their department and stated that surgery should be the initial treatment of choice. They also recommended postoperative radiation for high-grade malignancy, residual, or recurrent cases.

The approach is crucial in planning for surgical resection. In lateral craniotomy, such as IFTB, the third branch of the trigeminal nerve is sacrificed, thus the risk for developing TCR is present. TCR was first reported more than a century ago in animal studies by Kratschmer.<sup>2, 3</sup> This phenomenon is well known in clinical practice and has been reported in a number of neurosurgical and otolaryngological surgeries, such as cerebellopontine angle and peri-brainstem surgery,<sup>4</sup> trigeminal nerve surgery, transsphenoidal pituitary surgery, subdural abscess, Le Fort I osteotomy, and peri-ocular surgery. Schaller et al. reported that TCR occurred in 11% of skull base surgery in 1999.<sup>5</sup> A similar percentage of incidence (8.9%) was reported in a recent review.<sup>6</sup> TCR does not usually lead to significant sequelae; however, one case was reported to result in death.<sup>7</sup> In addition, another case reportedly induced coronary artery spasm.<sup>8</sup> Thus, the risk of mortalities related to TCR-induced cardiovascular events should be considered low but not absent. However, the underlying mechanism of the physiological function of the brainstem reflexes remains unclear. Schaller et al.<sup>9</sup> suggested empirically that the TCR may be a central reflex that causes rapid cerebral vasodilation resulting from the excitation of oxygen-sensitive nerves in the rostral medulla ventralis lateralis. Therefore, risk factors such as hypercapnia, hypoxemia, shallow anesthesia, and

children with vagal predominance and narcotic, preoperative beta-blocker and calcium antagonist use should be avoided whenever possible. Atropine administration is considered an appropriate treatment for TCR.<sup>9</sup>

The present case involved a tumor located at the skull base and required a lateral craniotomy and IFTB approach to ensure a wide view. A thorough screening for the risk factors for the development of TCR was required since the third branch of the trigeminal nerve will be severed during the procedure. We retrospectively reviewed the patient's history and status of anesthesia management for risk factors. The patient had no history of cardiac disease or epileptic seizures, and the occurrence of cardiac arrest during trigeminal nerve manipulation was thought to be due to TCR. The following were done: examining the patient's risk factors, SpO<sub>2</sub> was maintained at 100%, CO<sub>2</sub> concentrations were appropriately controlled, and intraoperative anesthesia depth was appropriate; therefore, the remaining contributing factor could be the potential effect of the drugs. Remifentanyl, one of the drugs used for this patient, has been widely used in Japan since around 2007 because of its short half-life. This drug may have been a possible trigger for TCR in this patient since it can cause severe bradycardia or cardiac arrest.<sup>10</sup> A change in anesthetic management medication may have been considered. Additionally, the administration of prophylactic medication for bradycardia before severing the third branch of the trigeminal nerve was needed. Atropine, an anticholinergic drug, is typically used for bradycardia or cardiac arrest and is effective in the management of TCR. In this case, it was only administered during the induction of anesthesia; therefore, no prophylactic effect was expected. In the event of cardiac arrest because of TCR, essential measures to restore sinus rhythm such as immediate surgical cessation, chest compressions, temporary cessation of remifentanyl, and administration of atropine or epinephrine must be done. Most importantly, careful collaboration with the anesthesiologist while manipulating the area around the trigeminal nerve is required to avoid complications.

In conclusion, we have described the resection of a chondrosarcoma using the IFTB and anterior petrosal approaches. TCR developed during the procedure. It is important to note that circulatory depression can occur while performing surgical manipulations around the trigeminal nerve, and preoperative consultation with the anesthesiologist is required. Postoperative radiation therapy was also administered, and the tumor is still in remission seven years after treatment.

*The authors declare no conflict of interest.*

## REFERENCES

- 1 Sbaihat A, Bacciu A, Pasanisi E, Sanna M. Skull base chondrosarcomas: surgical treatment and results. *Ann Otol Rhinol Laryngol.* 2013;122:763-70. DOI: 10.1177/000348941312201206, PMID: 24592579
- 2 Florian K. Über Reflexe von der Nasenschleimhaut auf Atmung und Kreislauf. *Sber Akad Wis Wien.* 1870;62:147-70.
- 3 Kratschmer F. On reflexes from the nasal mucous membrane on respiration and circulation. *Respir Physiol.* 2001;127:93-104. DOI: 10.1016/S0034-5687(01)00234-1, PMID: 11504582
- 4 Amirjamshidi A, Abbasioun K, Etezadi F, Ghasemi S. Trigemino-cardiac reflex in neurosurgical practice: report of two new cases. *Surg Neurol Int.* 2013;4:126. DOI: 10.4103/2152-7806.119053, PMID: 24233130
- 5 Schaller B, Probst R, Strebel S, Gratzl O. Trigemino-cardiac reflex during surgery in the cerebellopontine angle. *J Neurosurg.* 1999;90:215-20. DOI: 10.3171/jns.1999.90.2.0215, PMID: 9950491
- 6 Leon-Ariza DS, Leon-Ariza JS, Nangiana J, Vargas Grau G, Leon-Sarmiento FE, Quiñones-Hinojosa A. Evidences in Neurological Surgery and a Cutting Edge Classification of the Trigemino-cardiac Reflex: A Systematic Review. *World Neurosurg.* 2018;117:4-10. DOI: 10.1016/j.wneu.2018.05.208, PMID: 29883819
- 7 Fayon M, Gauthier M, Blanc VF, Ahronheim GA, Michaud J. Intraoperative cardiac arrest due to the oculocardiac reflex and subsequent death in a child with occult Epstein-Barr virus myocarditis. *Anesthesiology.* 1995;83:622-624. DOI: 10.1097/00000542-199509000-00024, PMID: 7661365
- 8 Kariya N, Toyoyama H, Furuichi K, Kubota H, Toyoda Y. Coronary artery spasm induced by trigeminal nerve stimulation and vagal reflex during intracranial operation. *J Neurosurg Anesthesiol.* 1999;11:203-5. DOI: 10.1097/00008506-199907000-00009, PMID: 10414677
- 9 Schaller B, Cornelius JF, Prabhakar H, Koerbel A, Gnanalingham K, Sandu N, et al.; Trigemino-Cardiac Reflex Examination Group (TCREG). The trigemino-cardiac reflex: an update of the current knowledge. *J Neurosurg Anesthesiol.* 2009;21:187-95. DOI: 10.1097/ANA.0b013e3181a2bf22, PMID: 19542994
- 10 DeSouza G, Lewis MC, TerRiet MF. Severe bradycardia after remifentanyl. *Anesthesiology.* 1997;87:1019-20. DOI: 10.1097/00000542-199710000-00061, PMID: 9357922