

Traumatic Gastric Perforation Associated with Cardiopulmonary Resuscitation: A Case Report

Yosuke Arai, Soichiro Honjo, Syota Shimizu, Masaki Morimoto, Masataka Amisaki, Tomohiro Osaki, Naruo Tokuyasu, Teruhisa Sakamoto, Yoshihiko Maeta, Keigo Ashida, Hiroaki Saito and Yoshiyuki Fujiwara

Division of Surgical Oncology, Department of Surgery, School of Medicine, Tottori University Faculty of Medicine, Yonago 683-8504, Japan

ABSTRACT

Sternal and rib fractures are well-known complications of cardiopulmonary resuscitation (CPR). We experienced a rare case of traumatic gastric perforation associated with CPR that required emergency laparotomy. In this case, we examined whether surgery is essential for gastric perforation associated with CPR. A 67-year-old man experienced cardiopulmonary arrest in the workplace, and bystander CPR was performed by his colleagues. He was then transported by ambulance to our hospital. A large amount of free air was found in the peritoneal cavity on computed tomography at presentation, and perforation of the gastrointestinal tract was suspected. During emergency laparotomy, a 2-cm serosal-muscular layer tear was found in the gastric lesser curvature. The damaged stomach wall was repaired, the abdominal cavity was lavaged, and surgery was completed by placing a drainage tube. The patient's postoperative course was good and he was discharged on the 26th postoperative day. Emergency laparotomy has been performed frequently for traumatic gastric perforation associated with CPR. However, emergency laparotomy may be avoided by conservative treatment in some cases. Traumatic gastric perforation associated with CPR is a serious complication; however, the life prognosis of cardiopulmonary arrest patients depends on the original disease and the success of CPR. Traumatic gastric perforation associated with CPR is rarely fatal, and bystanders should not hesitate to initiate CPR.

Key words cardiopulmonary resuscitation; emergency laparotomy; traumatic gastric perforation

Complications of cardiopulmonary resuscitation (CPR), such as sternal fracture, rib fracture, and skin damage, occur in 21%–65% of patients receiving CPR.¹ However,

traumatic gastric perforation is a rare complication that occurs at a rate of 0.1% during CPR.² We experienced a rare case of traumatic gastric perforation associated with CPR that required emergency laparotomy. In this case, we examined whether surgery is essential for gastric perforation associated with CPR.

PATIENT REPORT

A 67-year-old man experienced cardiopulmonary arrest (CPA) in the workplace, and colleagues administered bystander CPR. He was then transported by ambulance to our hospital. Although abdominal distension was observed on presentation, there were no signs of peritonitis; however, chest radiographs revealed free air under the right diaphragm (Fig. 1). Abdominal computed tomography revealed a large amount of free air in the peritoneal cavity and the lesser omentum (Fig. 2a); subcutaneous emphysema was also seen in the inguinal region (Fig. 2b).

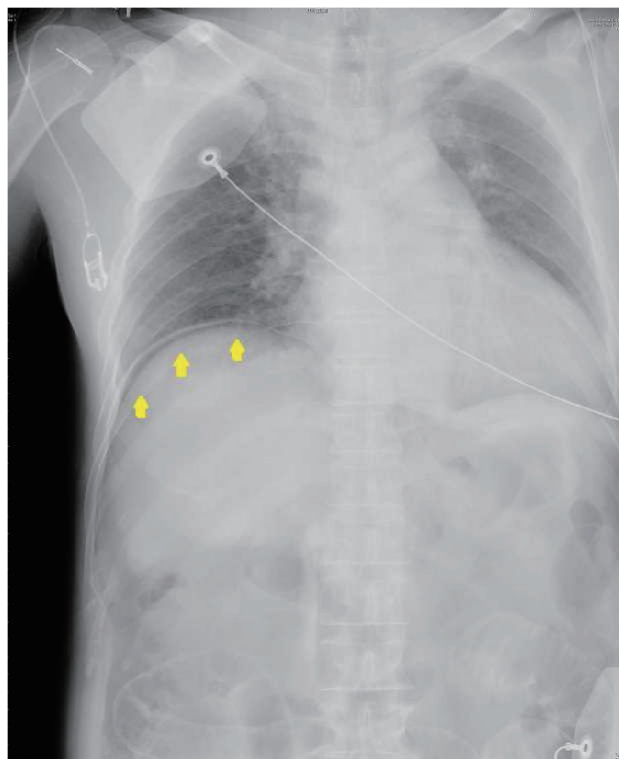


Fig. 1. Chest radiograph showing large volumes of right subdiaphragmatic free air (arrows).

Corresponding author: Soichiro Honjo, MD

honjo@med.tottori-u.ac.jp

Received 2017 June 19

Accepted 2017 August 25

Abbreviations: ALS, advanced life support; BLS, basic life support; CPA, cardiopulmonary arrest; CPR, cardiopulmonary resuscitation; POD, postoperative day

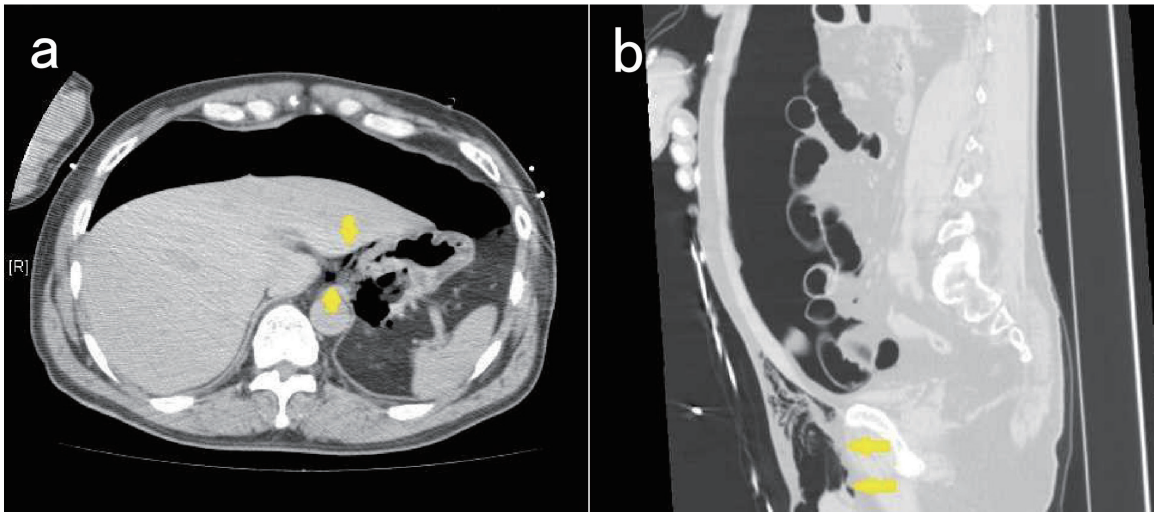


Fig. 2. Computed tomographic image. **a:** A large amount of air was found in the abdominal cavity causing pneumoperitoneum. We also recognized a small amount of air in the lesser omentum (*arrows*). **b:** Subcutaneous emphysema was observed in the inguinal area (*arrows*).

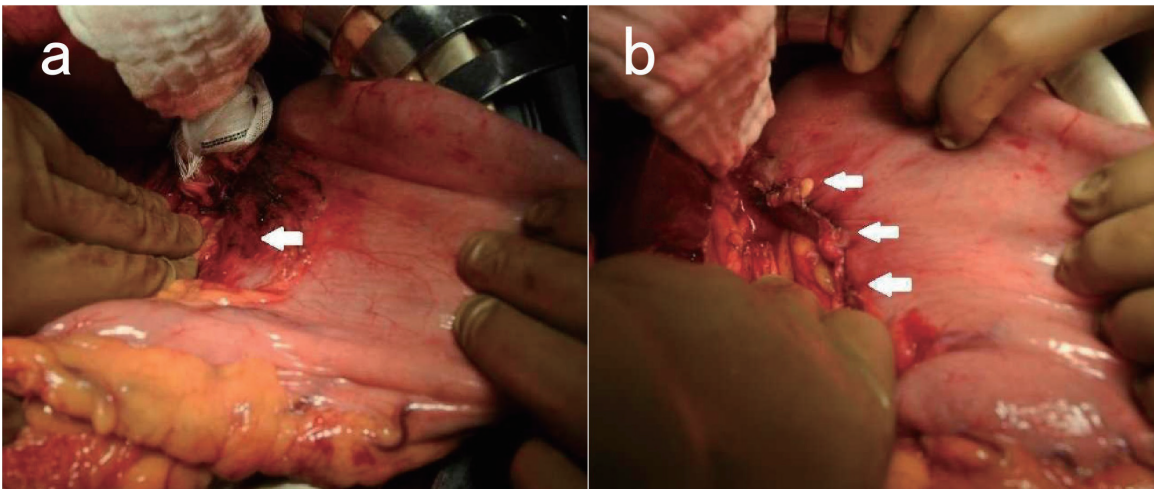


Fig. 3. Intraoperative findings. **a:** A large amount of air was found in the peritoneal cavity, but no food residue, digestive juice, or feces was found. We found a 2-cm tear in the serosal-muscular layer with hematoma in the gastric lesser curvature (*arrow*), and a fragile area in the stomach wall around the tear. **b:** The tear in the stomach wall was repaired including the fragile area (*arrows*). We inserted a drain near the repair site and completed the operation.

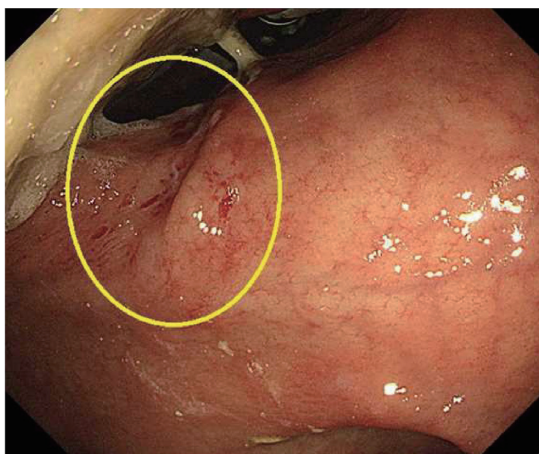


Fig. 4. The perforation site is healed and scarred (within the circle).

Based on these findings, we diagnosed upper gastrointestinal perforation following acute myocardial infarction confirmed with an electrocardiogram following CPA. Emergency cardiac catheterization and percutaneous coronary intervention were performed by a cardiovascular physician, which was followed by emergency laparotomy. Intraoperatively, a large amount of air with no offensive odor was found in the peritoneal cavity. However, no food residue, digestive juice, or feces were found; a small amount of normal physiological ascites was observed. We found a 2-cm serosal-muscular layer tear with hematoma in the gastric lesser curvature, and a fragile area in the stomach wall around the damaged site (Fig. 3a). The damaged stomach wall was repaired

including the fragile area (Fig. 3b), the abdominal cavity was lavaged, and surgery was completed by placing a drainage tube. The patient's postoperative course was good. The drainage tube was removed on the 5th postoperative day (POD). The nasogastric tube was removed on POD 7, and solid meals were started on POD 8. On POD 23, we confirmed healing of the perforation site with upper gastrointestinal endoscopy (Fig. 4), and the patient was discharged on POD 26 without neurological impairment.

DISCUSSION

We searched PubMed.gov for all cases of gastric perforation associated with CPR up to March 2017 using the keywords (perforation OR rupture OR pneumoperitoneum OR laceration) AND (gastric OR stomach) AND (resuscitation OR BLS OR ALS OR CPR OR cardiac arrest). The references in the retrieved publications were also searched for additional cases (Table 1).^{3–53} The median age was 68 years (range, 5 months–88 years), and the male-to-female ratio was nearly equal (37:34). Emergency laparotomy was performed in 48 of these patients (68.5%), and no patients had symptoms of peritonitis within the searchable range. The reasons for the lack of symptoms may be as follows: The main cause of traumatic gastric perforation associated with CPR is presumed to be that the stomach is markedly expanded by improper artificial respiration and that intragastric pressure rises rapidly when performing chest compressions. Unlike with perforations such as gastric ulcer, in cases of gastric perforation associated with CPR, perforation occurs after the stomach wall is stretched to the limit, and the mucosa and serosal muscular layer are torn separately. The result is that the mucosal rupture site and serosal-muscular layer rupture site do not match when the stomach collapses; therefore, the perforation path runs the gap of the submucosal layer and the muscular layer from the mucosal rupture site to the rupture site of the serosal muscular layer. Only air in the stomach, which has reached a very high pressure, can leak out of the stomach. Liquid and solids can barely pass through the rupture, which is why peritonitis symptoms do not develop, despite gastric perforation.

Once gastric rupture occurs, a large amount of air is released into the abdominal cavity because the stomach interior is under high pressure. Laparotomy is likely to be intuitively selected for gastric perforation with a large amount of free air; however, emergency laparotomy may not be necessary. What leaks into the peritoneal cavity is clean air because the stomach contains primarily artificially-delivered air, and there is almost no leakage of liquids and solids. Therefore, conservative treatment may

Table 1. Reports of traumatic gastric perforation associated with cardiopulmonary resuscitation

		<i>n</i> = 71
Age (years) (Median ± SD)		68 ± 18.4
Gender	Male	37
	Female	34
Cause of CPA	Cardiovascular disease	28
	Respiratory disease	17
	Others	16
	Unknown	10
CPR method	BLS (mouth to mouth)	43 (6)
	ALS	26
	Unknown	2
Attempted intubation	Yes	27
	No	44
Esophageal intubation (<i>n</i> = 27)	Yes	13
	No	14
Defibrillation	Yes	13
	No	58
Outcome of CPR	Successful	59
	Unsuccessful	12
Location of gastric perforation	Lesser	39
	Anterior	2
	Unknown	30
Treatment for perforation	Laparotomy	48
	Conservative	10
	None	12
	Unknown	1
Outcome	Alive	41
	Dead	30
Cause of death (<i>n</i> = 30)	Original disease	25
	Others	3
	Unknown	2
	Gastric perforation	0

ALS, advanced life support; BLS, basic life support; CPA, cardiopulmonary arrest; CPR, cardiopulmonary resuscitation.

be possible for traumatic gastric perforation associated with CPR. In cases where peritonitis can be ruled out based on physical and other examination findings, rather than moving quickly to laparotomy, we believe that careful follow-up observation with conservative treatments such as gastric decompression and antacid administration is an option. A patient's entire body condition is considered unstable after CPR, regardless of the underlying disease leading to the CPA; therefore, it is very beneficial to avoid emergency laparotomy immediately after CPR. It is useful to perform surgery of traumatic gastric perforation associated with CPR by laparoscopic surgery which is minimally invasive. However, considering the risk of general anesthesia, it should be limited to troublesome cases as to whether conservative treatment is possible or not.

In conclusion, emergency laparotomy has been

performed frequently for traumatic gastric perforation associated with CPR. However, emergency laparotomy may be avoided by conservative treatments in some cases. Traumatic gastric perforation associated with CPR is a serious complication; however, life prognosis for CPA patients depends on the original disease and the success of CPR. Traumatic gastric perforation associated with CPR is rarely fatal, and bystanders should not hesitate to initiate CPR.

The authors declare no conflict of interest.

REFERENCES

- Buschmann CT, Tsokos M. Frequent and rare complications of resuscitation attempts. *Intensive Care Med.* 2009;35:397-404. PMID: 18807013.
- Krischer JP, Fine EG, Davis JH, Nagel EL. Complications of cardiac resuscitation. *Chest.* 1987;92:287-91. PMID: 3608599.
- Demos NJ, Poticha SM. Gastric rupture occurring during external cardiac resuscitation. *Surgery.* 1964;55:364-6. PMID: 14133092.
- Valtonen EJ, Hakola N. Rupture of the normal stomach during mouth-to-mouth resuscitation. *Acta Chir Scand.* 1964;127:427-31. PMID: 14149645.
- Courbier R, Jaquenoud P, Baille Y, Henry E. Cardiac arrest and gastric perforation. *Agressologie.* 1966;7:271-6. PMID: 5937303.
- Anthony PP, Tattersfield AE. Gastric mucosal lacerations after cardiac resuscitation. *Br Heart J.* 1969;31:72-5. PMID: 5764968.
- Cassebaum WH, Carberry DM, Stefko P. Rupture of the stomach from mouth-to-mouth resuscitation. *J Trauma.* 1974;14:811-4. PMID: 4415663.
- Solowiejczyk M, Koren E, Wapnick S, Mandelbaum J. Rupture of the stomach following mouth-to-mouth respiration. *Postgrad Med J.* 1974;50:769-72. PMID: 4469046.
- Darke SG, Bloomfield E. Case of complete gastric rupture complicating resuscitation. *Br Med J.* 1975;3:414-5. PMID: 1156790.
- Ducable G, Chamoun S, Leturgie C, Watelet J, Winckler C. Gastric ruptures after resuscitation. *Anesth Analg.* 1978;35:1153-8. PMID: 754561.
- Matikainen M. Rupture of the stomach: a rare complication of resuscitation. *Acta Chir Scand.* 1978;144:61-2. PMID: 654838.
- Gisselsson L, Idvall J. Rupture of the stomach after heart-lung resuscitation. *Lakartidningen.* 1979;76:2898-9. PMID: 502655.
- Evans RD, Lighton JE. Gastric rupture as a complication of cardiopulmonary resuscitation: report of case and review of literature. *J Am Osteopath Assoc.* 1981;80:830-1. PMID: 7263324.
- McGrath RB. Gastroesophageal lacerations. A fatal complication of closed chest cardiopulmonary resuscitation. *Chest.* 1983;83:571-2. PMID: 6600676.
- Mills SA, Paulson D, Scott SM, Sethi G. Tension pneumoperitoneum and gastric rupture following cardiopulmonary resuscitation. *Ann Emerg Med.* 1983;12:94-5. PMID: 6600589.
- Shemesh E, Dreznik Z, Shechter P, Wolfstein I. Rupture of stomach due to external cardiac resuscitation. *Isr J Med Sci.* 1983;19:853-4. PMID: 6643028.
- Engelstein D, Stamler B. Gastric rupture complicating mouth-to-mouth resuscitation. *Isr J Med Sci.* 1984;20:68-70. PMID: 6698775.
- Gainant A, Bobeaux RF, Renaudie J, Voultoury JC, Cubertafond P, Gay R. Pneumoperitoneum following cardiorespiratory resuscitation procedures. *Presse Méd.* 1984;13:1845-6. PMID: 6236448.
- Krause S, Donen N. Gastric rupture during cardiopulmonary resuscitation. *Can Anaesth Soc J.* 1984;31:319-22. PMID: 6722623.
- Krohn CD, Buxrud T, Kummen O. Complications of cardiopulmonary resuscitation. *Tidsskr Nor Laegeforen.* 1984;104:2253-4. PMID: 6523459.
- van der Loos TL, Lustermaans FA. Rupture of the normal stomach after therapeutic oxygen administration. *Intensive Care Med.* 1986;12:52-3. PMID: 3711428.
- Vinen JD, Gaudry PL. Pneumoperitoneum complicating cardiopulmonary resuscitation. *Anaesth Intensive Care.* 1986;14:193-6. PMID: 3740392.
- Woods SD, Hutchinson G, Johnson WR, Masterton JP. Gastric rupture following cardiopulmonary resuscitation. *Aust N Z J Surg.* 1986;56:733-5. PMID: 3467706.
- Custer JR, Polley Jr TZ, Moler F. Gastric perforation following cardiopulmonary resuscitation in a child: report of a case and review of the literature. *Pediatr Emerg Care.* 1987;3:24-7. PMID: 3562308.
- Floret D, Melki I, Philibert N, Takvorian P. Gastric rupture and resuscitation maneuvers. *Pediatric.* 1987;42:95-7. PMID: 3615143.
- Varekamp AP, Liem BK. Gastric rupture: a rare complication of resuscitation. *Neth J Surg.* 1987;39:198. PMID: 3431724.
- Hargaten KM, Aprahamian C, Mateer J. Pneumoperitoneum as a complication of cardiopulmonary resuscitation. *Am J Emerg Med.* 1988;6:358-61. PMID: 3291885.
- Skulberg A, Steen PA. Ventricular rupture after mouth-to-mouth resuscitation without tube. *Tidsskr Nor Laegeforen.* 1988;108:215-24. PMID: 3353915.
- Armbruster C, Dittich K, Tuchmann A. Stomach rupture—a rare complication of resuscitation. *Chirurg.* 1989;60:178-9. PMID: 2721298.
- Hulewicz B. Gastric trauma following cardiopulmonary resuscitation. *Med Sci Law.* 1990;30:149-52. PMID: 2348769.
- Cameron PA, Rosengarten PL, Johnson WR, Dziukas L. Tension pneumoperitoneum after cardiopulmonary resuscitation. *Med J Aust.* 1991;155:44-7. PMID: 2067438.
- Hartoko TJ, Demey HE, Rogiers PE, Decoster HL, Nagler JM, Bossaert LL. Pneumoperitoneum—a rare complication of cardiopulmonary resuscitation. *Acta Anaesthesiol Scand.* 1991;35:235-7. PMID: 2038930.
- Low LL, Ripple GR, Bruderer BP, Harrington GR. Non-operative management of gastric perforation secondary to cardiopulmonary resuscitation. *Intensive Care Med.* 1994;20:442-3. PMID: 7798450.
- Liu N, Boyle K, Bertrand C, Bonnet F. Stomach rupture during CPR. *Ann Emerg Med.* 1996;27:105-6. PMID: 8572441.
- Miller JS, Itani KM, Oza MD, Wall MJ. Gastric rupture with tension pneumoperitoneum: a complication of difficult endotracheal intubation. *Ann Emerg Med.* 1997;30:343-6. PMID: 9287899.
- Reiger J, Eritscher C, Laubreiter K, Trattng J, Sterz F, Grimm G. Gastric rupture—an uncommon complication after suc-

- cessful cardiopulmonary resuscitation: report of two cases. *Resuscitation*. 1997;35:175-8. PMID: 9316204.
- 37 Oh CM, Hewitt PM. Gastric rupture due to cardiopulmonary resuscitation. *Injury*. 1998;29:399-400. PMID: 9813691.
 - 38 Strear CM, Jarnagin WR, Schechter W, Mackersie RC, Hickey MS. Gastric rupture and tension pneumoperitoneum complicating cardiopulmonary resuscitation: case report. *J Trauma*. 1998;44:930-2. PMID: 9603105.
 - 39 Piardi T, D'Adda F, Palmieri F, Vettoretto N, Lanzi S, Pouchè A. Shock and dyspnea after cardiopulmonary resuscitation: a case of iatrogenic gastric rupture. *Chir Ital*. 2000;52:593-6. PMID: 11190556.
 - 40 Offerman SR, Holmes JF, Wisner DH. Gastric rupture and massive pneumoperitoneum after bystander cardiopulmonary resuscitation. *J Emerg Med*. 2001;21:137-9. PMID: 11489402.
 - 41 Tung PH, Law S, Chu KM, Law WL, Wong J. Gastric rupture after Heimlich maneuver and cardiopulmonary resuscitation. *Hepatogastroenterology*. 2001;48:109-11. PMID: 11268942.
 - 42 Smally AJ, Ross MJ, Huot CP. Gastric rupture following bag-valve-mask ventilation. *J Emerg Med*. 2002;22:27-9. PMID: 11809553.
 - 43 Haslam N, Campbell GC, Duggan JE. Gastric rupture associated with use of the laryngeal mask airway during cardiopulmonary resuscitation. *BMJ*. 2004;329:1225-6. PMID: 15550427.
 - 44 Keldahl M, Sen S, Gamelli RL. Gastric rupture after cardiopulmonary resuscitation in a burn patient. *J Burn Care Res*. 2006;27:757-9. PMID: 16998412.
 - 45 Lin PY, Tsai MS, Chang JH, Chen WJ, Huang CH. Gastric distension: a risk factor of pneumoperitoneum during cardiopulmonary resuscitation. *Am J Emerg Med*. 2006;24:878-9. PMID: 17098114.
 - 46 Campillo-Soto A, Lirón-Ruiz R, Torralba-Martínez JA, Morales-Cuenca G, del Pozo P, Aguayo-Albasini JL. Gastric rupture and massive pneumoperitoneum after cardiopulmonary resuscitation by lay persons. *Cir Esp*. 2007;81:49-51. PMID: 17263960.
 - 47 Hahn CD, Choi YU, Lee D, Frizzi JD. Pneumoperitoneum due to gastric perforation after cardiopulmonary resuscitation: case report. *Am J Crit Care*. 2008;17:386-7. PMID: 18593840.
 - 48 Sajith A, O'Donohue B, Roth RM, Khan RA. CT scan findings in oesophagogastric perforation after out of hospital cardiopulmonary resuscitation. *Emerg Med J*. 2008;25:115-6. PMID: 18212156.
 - 49 Spoormans I, Van Hoorenbeeck K, Balliu L, Jorens PG. Gastric perforation after cardiopulmonary resuscitation: review of the literature. *Resuscitation*. 2010;81:272-80. PMID: 20064683.
 - 50 Jalali SM, Emami-Razavi H, Mansouri A. Gastric perforation after cardiopulmonary resuscitation. *Am J Emerg Med*. 2012;30:2091. PMID: 22867822.
 - 51 Afacan MA, Colak S, Gunes H, Kandis H, Saritas A, Ozaydin I, et al. An unusual complication of cardiopulmonary resuscitation: stomach perforation. *Am J Emerg Med*. 2014;32:1149.e1-3. PMID: 24666745.
 - 52 Wolff AT, Hohenstein C. Gastric perforation after mouth-to-mouth ventilation: a case report. *Eur J Anaesthesiol*. 2015;32:138-9. PMID: 25105849.
 - 53 Mani VR, Pradhan L, Gray S. Development of pneumoperitoneum after CPR. *Int J Surg Case Rep*. 2015;6C:40-2. PMID: 25506850.