

Recipient Vessel Selection in Head and Neck Reconstruction Based on the Type of Neck Dissection

Shunjiro Yagi,* Yoshiko Suyama,* Kohei Fukuoka,* Hiromi Takeuchi† and Hiroya Kitano†

*Departments of Plastic and Reconstructive Surgery, Tottori University Hospital, Yonago 683-8504, Japan and †Division of Otolaryngology, Head and Neck Surgery, Department of Sensory and Motor Organs, School of Medicine, Tottori University Faculty of Medicine, Yonago 683-8503, Japan

ABSTRACT

Background Recipient vessel selection in head and neck reconstruction using free flap transfers has to be standardized. However, the recipient vessel selection based on the type of neck dissection has yet to be investigated. We describe the relationship between the type of neck dissection and recipient vessel.

Methods Records of 107 consecutive patients who had undergone head and neck reconstruction using free flap transfers from 2011 to 2015 were reviewed retrospectively. Ninety-five were men and 12 were women, with a mean age of 65.6 years. Patients were divided into 5 groups based on the type of neck dissection: no neck dissection (NND, $n = 17$), upper jugular neck dissection, (UJND, $n = 1$), supraomohyoid neck dissection (SOND, $n = 18$), jugular neck dissection (JND, $n = 39$), and modified radical neck dissection (mRND, $n = 32$). We details the number of recipient vessels we selected for free tissue transfer in head and neck reconstruction depending on the type of neck dissection.

Results The overall patency rate was 100%. The superficial temporal artery was used most frequently in NND; the superior thyroid artery in SOND; the transverse cervical artery in JND; and the transverse cervical artery in mRND. The superficial temporal vein was used most frequently in NND; The internal jugular vein in the SOND; and The external jugular vein in mRND.

Conclusion Microsurgeons should remember that proper recipient vessel selection depending on the type of neck dissection is important. We believe proper recipient vessel selection should improve results of head and neck reconstruction using free flap transfer.

Key words free flap; head and neck reconstruction; microsurgery; neck dissection; recipient vessel

Free flap transfer is an essential technique in head and neck reconstruction, and the success of free flap transfers depends on the quality of the vascular microanastomoses. Selective neck dissection is often performed to preserve function and minimize cosmetic deformity in cases of limited local invasion. Recipient vessel selection in head and neck reconstruction has been the subject of numerous reports.^{1–3} However, the recipient vessel selection based on the type of neck dissection has yet to be investigated. Tumor resection and flap harvest are often performed simultaneously, and flap design and pedicle length usually are determined once the shape of the defect and recipient vessel availability is known. We suppose that recipient vessel selection should be part of preoperative planning in head and neck reconstruction. Here, we describe the relationship between the type of neck dissection and selection of recipient vessel.

MATERIALS AND METHODS

Between January 2011 and December 2015, we performed 107 head and neck reconstructions with free flap transfers. There were 95 men and 12 women with a mean age 65.6 years. Thirteen patients (12.1%) had undergone prior neck preoperative radiation therapy with average dose of 40.6 Gy, and 59 patients (55.1%) had received preoperative chemotherapy. Tables 1 and 2 present the numbering system used to identify the structures resected and the type of free flap used for reconstruction.

The range and type of neck dissection were classified into four groups based on Memorial Sloan-Kettering Cancer Center's (MSKCC) classification system (Fig. 1).⁴ No neck dissection (NND, $n = 17$) lymphadenectomy, upper jugular neck dissection (UJND, $n = 1$) including level I lymphadenectomy, supraomohyoid neck dissection (SOND, $n = 18$) including level I to III lymphadenectomy, jugular neck dissection (JND, $n = 39$) including level II to IV lymphadenectomy. Modified radical neck dissection (mRND, $n = 32$) including level I to V lymphadenectomy. The external jugular veins were prepared as a recipient vein whenever possible in all groups. The number of the type of neck dissection were summarized for the side where microanastomosis were

Corresponding author: Shunjiro Yagi, MD, PhD

yagishun@med.tottori-u.ac.jp

Received 2016 March 25

Accepted 2016 April 22

Abbreviations: JND, jugular neck dissection; mRND, modified radical neck dissection; NND, no neck dissection; SOND, supraomohyoid neck dissection; UJND, upper jugular neck dissection

performed, and we counted the number of recipient vessels we selected for free tissue transfer in head and neck reconstruction depending on the type of neck dissection.

RESULTS

The overall patency rate was 100%. The number of arterial anastomoses by dissection group was as follows: NND, 17 patients; UJND, 1 patient; SOND, 18 patients; JND, 39 patients; and mRND, 32 patients. The superficial temporal artery was used most frequently in NND (10 patients, 58.8%); the superior thyroid artery was used most frequently in SOND (13 patients, 72.2%); the transverse cervical artery was most common in JND 33 patients, 84.6%); and the transverse cervical artery was most common in mRND (27 patients, 84.4%) (Table 3).

The number of venous anastomosis was 130 because 2 different recipient veins were used in 23 patients. The

superficial temporal vein was used most frequently in NND (10 patients, 55.6%); The internal jugular vein was the most common recipient vein in the SOND (16 patients, 57.1%). and The external jugular vein was the most common recipient vein in mRND (29 patients, 69%) while the external jugular vein (18 necks, 45%) and the internal jugular vein (19 patients, 47.5%) have similar frequency in the JND, (Table 4).

DISCUSSION

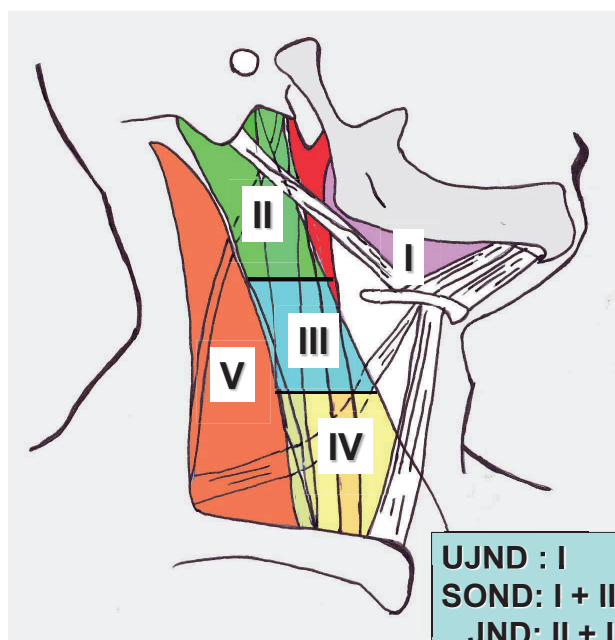
Free flap transfer has become indispensable in head and neck reconstruction, with a success rate of over 95 %.²⁻⁵⁻⁸ Selection of a suitable recipient vessel is essential for success, yet the complex vascular anatomy of the head and neck can complicate vessel selection.³ Historically, the choice of recipient vessel has depended on the personal experience of the surgeon more than on objective

Table 1. Regions requiring reconstruction following head and neck surgery

Site of reconstruction	Number
Tongue, oral cavity	27
Mesopharynx	15
Hypopharynx	42
Upper 1/3 of the head	7
Middle 1/3 of the head	7
Lower 1/3 of the head	9
Total	107

Table 2. Flaps used for head and neck reconstruction

Flap	Number
Jejunal flap	44
Rectus abdominis musculocutaneous flap	29
Anterolateral thigh flap	14
Latissimus dorsi musculocutaneous flap	8
Forearm flap	6
Fibular flap	4
Omental flap	2
Total	107



UJND : I
SOND: I + II + III
JND: II + III + IV
mRND: I + II + III + IV + V

Fig. 1. A diagram showing levels of cervical lymph nodes. **I:** submental and submandibular; **II:** upper jugular; **III:** middle jugular; **IV:** lower jugular; **V:** posterior triangle. JND, jugular neck dissection; mRND, modified radical neck dissection; NND, no neck dissection; SOND, supraomohyoid neck dissection; UJND, upper jugular neck dissection.

data.

Conventional radical neck dissection is very invasive surgery. In RND, cervical tissue, including accessory nerve, the internal jugular vein and the sternocleidomastoid muscle are removed. This radical procedure results in numerous postoperative complications.⁹ MRND was developed to minimize morbidity and mortality.¹⁰⁻¹² We arbitrarily divided our cases into four groups based roughly on MSKCC's classification system⁴ because Japan has no official name or classification system for neck dissection.

Nahabedian et al.³ have discussed the relationship between recipient vessels and the donor site. The superficial temporal artery and vein are used in the upper third of the head, the facial and superior thyroid artery and vein for the lower third of the face, and the carotid artery and jugular vein, along with their various branches, in the neck. We usually used the facial or superficial temporal vessels in NND because the facial and superficial temporal artery can be palpated through the skin easily, and these veins run concomitantly. However, the facial vein sometimes is excessively ramified and remains too

small even for a microanastomosis. In such cases, the incision is extended inferiorly and the external jugular vein is used. The external jugular vein is easily traced by compressing the lower neck. In SOND, only arteries within the submandibular triangle and the carotid triangle are exposed, and the facial artery and the lingual artery are sometimes ligated, so the superior thyroid artery is the first choice for the recipient artery.

In mRND, the transverse cervical artery is the first choice. The transverse cervical artery always passes behind the omohyoid and anterior scalene muscle and is long enough to reach the flap pedicle in head and neck reconstruction.¹³ However the path of the transverse cervical vein is more variable,^{13, 14} so the external jugular vein is a better choice. In JND, the superior thyroid and transverse cervical artery are useful because they are prepared easily after neck dissection. The external jugular vein is the first choice for recipient vein; however, the internal jugular vein is exposed for its full cervical length, so the internal jugular vein is a viable alternative.

Selecting the external jugular vein for the recipient vein offers several advantages. First, the head and

Table 3. Recipient artery as a type of neck dissection group

	NND	UJND	SOND	JND	mRND
Superficial temporal artery	10 (58.8%)				
Lingual artery			1 (5.6%)		
Superior thyroid artery	1 (5.9%)		13 (72.2%)	4 (10.3%)	3 (9.4%)
Facial artery	6 (35.3%)	1 (100%)	4 (22.2%)	2 (5.1%)	2 (6.3%)
Transverse cervical artery				33 (84.6%)	27 (84.4%)
Total	17	1	18	39	32

(n = 107)

JND, jugular neck dissection; mRND, modified radical neck dissection; NND, no neck dissection; SOND, supraomohyoid neck dissection; UJND, upper jugular neck dissection.

Table 4. Recipient vein as a type of neck dissection group

	NND	UJND	SOND	JND	mRND
Superficial temporal vein	10 (55.6%)				
Facial vein	5 (27.8%)	1 (50%)	2 (7.1%)	2 (5%)	
Superior thyroid vein			2 (7.1%)		
External jugular vein	3 (16.7%)	1 (50%)	8 (28.6%)	18 (45%)	29 (69%)
Transverse cervical vein				1 (2.5%)	2 (4.8%)
Posterior cervical vein					2 (4.8%)
Internal jugular vein			16 (57.1%)	19 (47.5%)	9 (21.4%)
Total	18	2	28	40	42

(n = 130)

JND, jugular neck dissection; mRND, modified radical neck dissection; NND, no neck dissection; SOND, supraomohyoid neck dissection; UJND, upper jugular neck dissection.

neck surgeon generally prepares the external jugular vein during neck dissection, so this vessel is usually available. Second, color-flow doppler and computed tomography studies have shown a 14 to 26.4% incidence of internal jugular vein thrombosis within 1 week after functional and selective cervical lymph- node dissection.^{15, 16} Third, we use a coupling device frequently for the venous anastomosis and these devices are unsuitable for end-to-side anastomosis, as Ahn reported.¹⁷ Use of a coupling device saves time and reduces the surgeon's load. Finally the external jugular vein is long and mobile making it quite adaptable.

Despite these advantages in using the external jugular vein as a recipient vessel, we use the internal jugular vein most frequently in SOND. We suppose one of the reasons for postoperative thrombosis in internal jugular vein is twist of the vein. The risk of venous twist is small because lower part of the internal jugular vein is not dissected in SOND. And venous blood flow of internal jugular vein is reliable. So, both the internal jugular and external jugular veins were selected as recipient vein at the same time in SOND.

Neck dissection is standardized to a great extent and therefore which recipient vessels to use for microanastomoses can to some extent be determined preoperatively. The choice will depend most strongly on the donor site for the free flap and the length of the vascular pedicle. We believe proper positioning depends only on the relation between the vascular pedicle and the recipient vessels. Microsurgeons should remember that proper recipient vessel selection depending on the type of neck dissection is important and this leads to improve results of head and neck reconstruction using free flap transfer.

Acknowledgments: The authors thank Bin Nakayama M.D., Ph.D., for his surgical support.

The authors declare no conflict of interest.

REFERENCES

- 1 Chia HL, Wong CH, Tan BK, Tan KC, Ong YS. An algorithm for recipient vessel selection in microsurgical head and neck reconstruction. *J Reconstr Microsurg.* 2011;27:47-56. PMID: 20976669.
- 2 Mulholland S, Boyd JB, McCabe S, Gullane P, Rotstein L, Brown D, et al. Recipient vessels in head and neck microsurgery: Radiation effect and vessel access. *Plast Reconstr Surg.* 1993;92:628-32. PMID: 8356125.
- 3 Nahabedian MY, Singh N, Deune EG, Silverman R, Tufaro AP. Recipient vessel analysis for microvascular reconstruction of the head and neck. *Ann Plast Surg.* 2004;52:148-55. PMID: 14745264.
- 4 Shah JP, Strong E, Spiro RH, Vikram B. Surgical grand rounds. Neck dissection: current status and future possibilities. *Clin Bull.* 1981;11:25-33. PMID: 6791863.
- 5 Khouri RK, Coolley BC, Kunselman AR, Landis JR, Yeramian P, Ingram D, et al. A prospective study of microvascular free-flap surgery and outcome. *Plast Reconstr Surg.* 1998;102:711-21. PMID: 9727436.
- 6 Wei FC, Demirkan F, Chen HC, Chuang DC, Chen SH, Lin CH, et al. The outcome of failed free flap in head and neck and extremity reconstruction: What is next in the reconstructive ladder? *Plast Reconstr Surg.* 2001;108:1154-60. PMID: 11604621.
- 7 Wei FC, Celik N, Chen HC, Cheng MH, Huang WC. Combined anterolateral thigh flap and vascularized fibula osteoseptocutaneous flap in reconstruction of extensive composite mandibular defects. *Plast Reconstr Surg.* 2002;109:45-52. PMID: 11786790.
- 8 Yagi S, Kamei Y, Torii S. Donor side selection in mandibular reconstruction using a free fibular osteocutaneous flap. *Ann Plast Surg* 2006;56:622-7. PMID: 16721074.
- 9 Genden EM, Felio A, Shaha AR, Talmi YP, Robbins KT, Rhys-Evans Ph, et al. Complication of neck dissection. *Acta Otolaryngol.* 2003;123:795-801. PMID: 14575393.
- 10 Chu W and Strawits JG. Results in suprahyoid, modified radical and standard radical neck dissections for metastatic squamous cell carcinoma: Recurrence and survival. *Am J Surg.* 1978;136:512-5. PMID: 707733.
- 11 Jesse RH, Ballantyne AJ and Larson D. Radical or modified neck dissection: a therapeutic dilemma. *Am J Surg.* 1978;136:516-9. PMID: 707734.
- 12 Bocca E, Pignataro O, Oldoni C, Calla C. Functional neck dissection: an evaluation and review of 843 cases. *Laryngoscope.* 1984;94:942-5. PMID: 6738274.
- 13 Yu P. The transverse cervical vessels as recipient vessels for previously treated head and neck cancer patients. *Plast Reconstr Surg.* 2005;115:1253-9. PMID: 15809582.
- 14 Goodwin WJ Jr and Resenberg GJ. Venous drainage of the lateral trapezius musculocutaneous island flap. *Arch Otolaryngol.* 1982;108:411-3. PMID: 7092682.
- 15 Quraishi HA, Wax MK, Granke K, Rodmam SM. Internal jugular vein thrombosis after functional and selective neck dissection. *Arch Otolaryngol Head Neck Surg.* 1997; 123:969-973. PMID: 9305248.
- 16 Brown DH, Mulholland S, Yoo JH, Gullane PJ, Irish JC, Neligan P, et al. Internal jugular vein thrombosis following modified neck dissection: Implications for head and neck flap reconstruction. *Head Neck.* 1998;20:169-74. PMID: 9484949.
- 17 Ahn CY, Shaw WW, Berns S, Markowitz BL. Clinical experience with the 3M microvascular coupling anastomotic device in 100 free-tissue transfers. *Plast Reconstr Surg.* 1994;93:1481-4. PMID: 8208815.