

The Expression of Melanoma Inhibitory Activity on Mast Cells in Child Patients with Cutaneous Mastocytosis

Yuko Ehara, Yuichi Yoshida, Makoto Tahira and Osamu Yamamoto

Division of Dermatology, Department of Medicine of Sensory and Motor Organs, School of Medicine, Tottori University Faculty of Medicine, Yonago 683-8504, Japan

ABSTRACT

Background Cutaneous mastocytosis is a disorder characterized by the proliferation of mast cells in the skin. Melanoma inhibitory activity (MIA) is a serum marker for malignant melanoma. However, it has not been known on MIA expression of cutaneous mastocytosis.

Methods We investigated the expression of MIA in 4 child patients with cutaneous mastocytosis immunohistochemically and serum MIA level in 1 patient by enzyme-linked immunosorbent assay.

Results Histopathological examination revealed diffuse mast cell infiltration in the dermis. MIA was positive for infiltrating mast cells in all patients. Serum level of MIA was elevated in 1 patient.

Conclusion Although it was difficult to assess the significance of elevated serum levels of MIA in child patients, MIA was expressed on infiltrating mast cells in our study. Based on our findings, mast cell-derived MIA might be related to the formation of pigmented regions in cutaneous mastocytosis.

Key words immunohistochemistry; mast cells; mastocytosis; melanocyte; melanoma inhibitory activity

Mastocytosis is a disorder characterized by the proliferation and accumulation of mast cells in the skin and/or other organs (systemic mastocytosis). It is known that about 80% of patients are cutaneous mastocytosis.¹ Cutaneous mastocytosis is classified into urticaria pigmentosa, solitary mastocytoma and diffuse cutaneous mastocytosis. Melanoma inhibitory activity (MIA) is an 11-kD protein that is used as a serum marker for malignant melanoma.² Recently, we have shown that MIA is expressed on mast cells of neurofibroma in patients with neurofibromatosis type 1 (NF1).³ However, it has not been clear on MIA expression of cutaneous mastocytosis. Therefore, we investigated the expression of MIA in 4 patients with cutaneous mastocytosis. We herein

Corresponding author: Yuko Ehara, MD

yukoehara@med.tottori-u.ac.jp

Received 2014 May 16

Accepted 2014 June 3

Abbreviations: MIA, melanoma inhibitory activity; NF1, neurofibromatosis type 1

report an expression of MIA on mast cells in patients with cutaneous mastocytosis and discuss its clinical significance.

MATERIALS AND METHODS

Four patients with cutaneous mastocytosis were studied. Immunohistochemistry of formalin-fixed and paraffin-embedded sections was performed by using the standard automated avidin-biotin complex method. The sections were incubated with anti-MIA antibody (5 µg/mL, R&D Systems, Minneapolis, MN) for 30 min at room temperature. They were then incubated for 30 min with a universal secondary antibody with a RED Map kit (Ventana Medical Systems, Tucson, AZ). Toluidine-blue staining was also performed. Serum MIA level was assayed by using an MIA enzyme-linked immunosorbent assay kit (Roche, Mannheim, Germany).

RESULTS

Patient reports

Patient 1: A 1-year-old boy presented with multiple brown macules on the trunk (Fig. 1a). His mother had noticed pigmented macules 8 months before presentation. Since the number of the region had increased, he was referred to our department. On physical examination, Darier's sign was positive on the macule. Family histories were unremarkable. Based on clinical and histopathological examinations, a diagnosis of urticaria pigmentosa was made.

Patient 2: A 2-year-old boy presented with a 20-month history of multiple brown macules on the abdomen and lower extremities. Darier's sign was positive on the macule. Based on clinical and histopathological examinations, a diagnosis of urticaria pigmentosa was made.

Patient 3: An 8-month-old boy presented with a brown nodule, 14 × 7 mm in size on the right side of abdomen (Fig. 1b). Based on clinical and histopathological examinations, a diagnosis of solitary mastocytoma was made.

Patient 4: A 1-year and 9-month-old boy presented with a 14-month history of multiple brown macules on the ex-

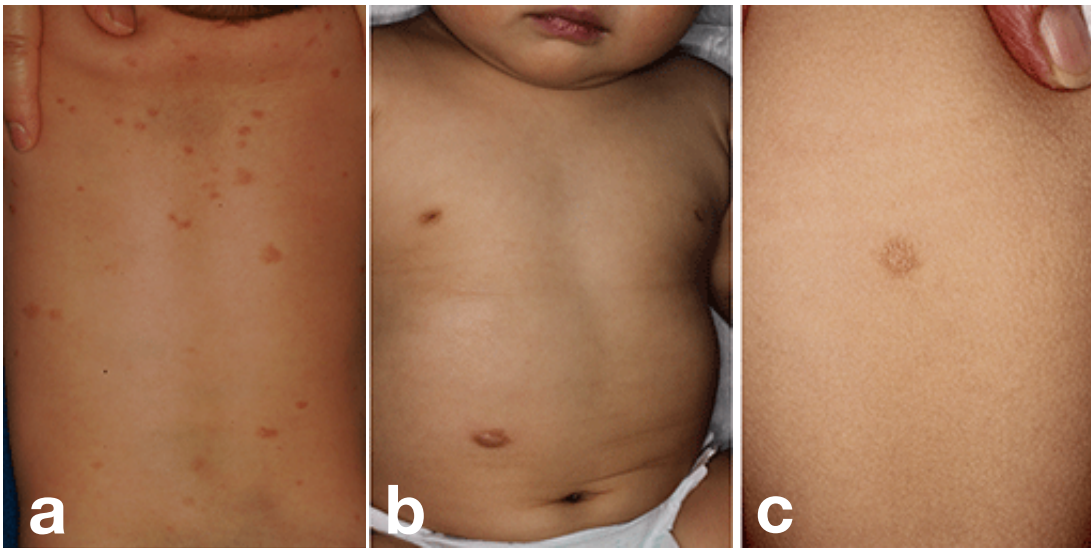


Fig. 1. Clinical features in Patients 1, 3 and 4.

- a:** Multiple reddish-brown macules on the back in Patient 1.
- b:** A brown nodule on the right side of abdomen in Patient 3.
- c:** Multiple brown macules on the extremities in Patient 4.

trémities (Fig. 1c). Based on clinical and histopathological examinations, a diagnosis of urticaria pigmentosa was made. There was no evidence of systemic involvement in all patients.

Histopathology

Histopathological examination revealed a diffuse mast cell infiltration in the dermis in all patients (Fig. 2a: Patient 1). Toluidine-blue staining showed metachromaric granules in the infiltrating cells (Fig. 2b: Patient 4). Immunohistochemically, most of infiltrating mast cells were strongly positive for MIA (Fig. 2c: Patient 1).

Serum level of MIA

Serum level of MIA was 21.5 ng/mL in Patient 4 (normal, healthy adult < 8.8 ng/mL).⁴

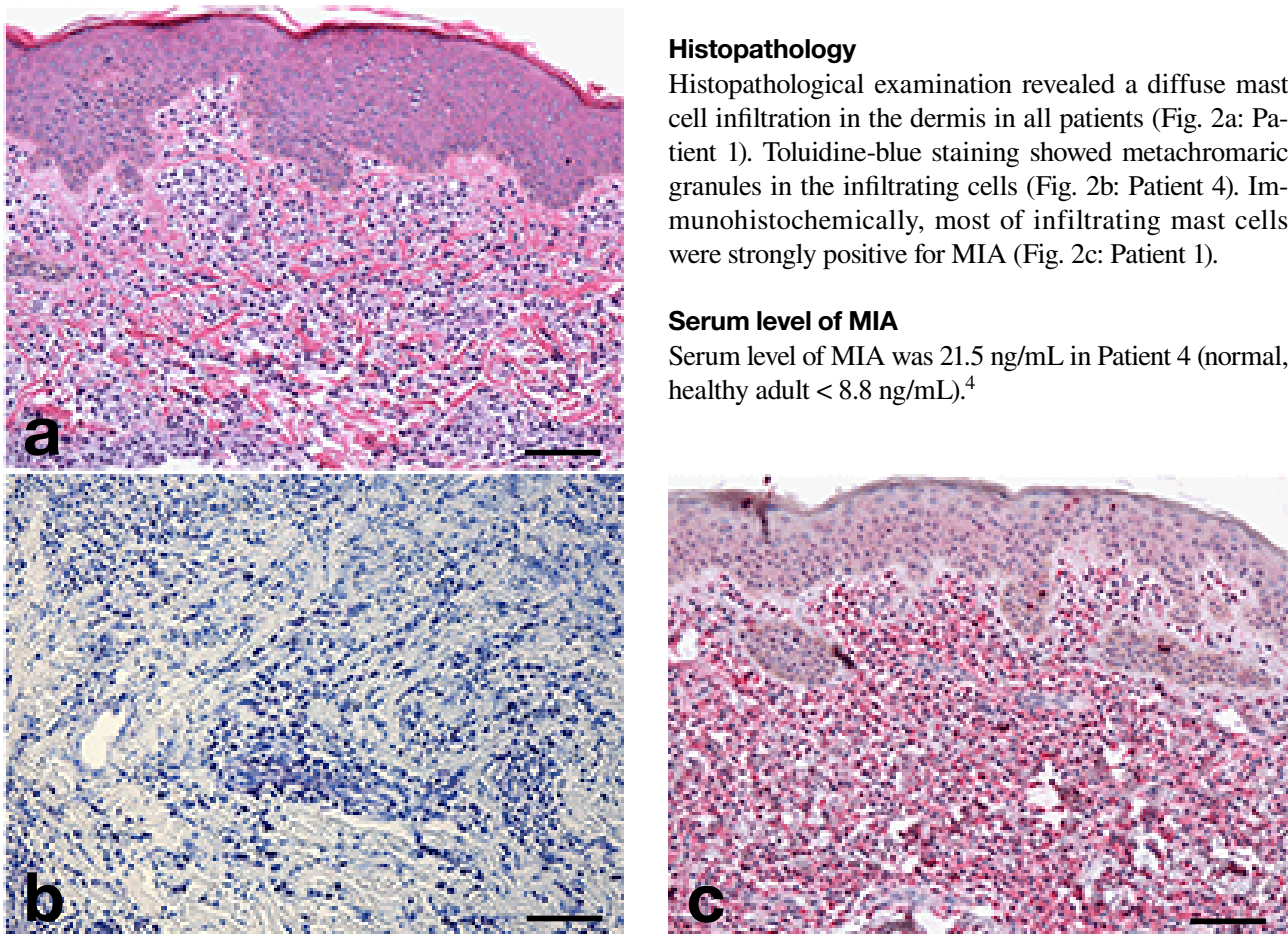


Fig. 2. Histopathological examination.

- a:** Diffuse mast cell infiltration in the dermis in Patient 1 (hematoxylin and eosin). Bar = 500 µm.
- b:** Infiltrating cells are positive for toluidine-blue staining in Patient 4. Bar = 250 µm.
- c:** Most of mast cells are positive for melanoma inhibitory activity in Patient 1. Bar = 500 µm.

Table 1. Cutaneous mastocytosis in this report

Pa-tient	Age	Sex	Diag-nosis	MIA staining	Serum MIA (ng/mL)
1	1 yr	Male	UP	+	ND
2	2 yr	Male	UP	+	ND
3	8 mo	Male	CM	+	ND
4	1 yr 9 mo	Male	UP	+	21.5

CM, cutaneous mastocytoma; MIA, melanoma inhibitory activity; ND, not done; UP, urticaria pigmentosa.

The results of these patients are shown in Table 1.

DISCUSSION

Mastocytosis is a rare disease characterized by the proliferation of mast cells in tissues. In children, mast cell hyperplasia is restricted to the skin in most patients in contrast to adult patients with systemic involvement.⁵ It is known that childhood-onset mastocytosis often goes into remission. Since we have previously found that MIA is expressed on mast cells of neurofibroma in patients with NF1,³ we were interested in MIA expression in mastocytosis. As expected, MIA was also expressed on mast cells in child patients with cutaneous mastocytosis. It has been reported that blood serotonin levels are related to clinical symptoms.⁶ In addition, it is known that elevation of basal tryptase levels are risk factors for anaphylaxis.⁷ Since MIA might be a potential biomarker in cutaneous mastocytosis, we investigated serum levels of MIA in 1 patient. Serum level of MIA was actually elevated in those patients. However, it has been reported that serum levels of MIA in children were usually elevated compared with those in adults because MIA is also expressed in chondrocytes.⁴ Therefore, it was difficult to assess the significance of elevated serum levels of MIA in child patients with cutaneous mastocytosis. The mutations of c-kit has been identified in adult-, but not in childhood-onset mastocytosis.⁸ Since MIA was also expressed on mast cells in normal skin (not shown) as well as neurofibromas in NF1, the expression may not be specific for mast cells in child-onset cutaneous mastocytosis. Although the mechanisms of MIA expression on mast cells are unknown, it has been reported that MIA shares structural homologies with some integrins and has a function for an inhibition of apoptosis in melanocytic cells.⁹ In addition, the transcription factor, SOX10 has been highly relevant for melanoma development and survival, and that SOX10 inhibition reduced MIA

expression and promoter activity.¹⁰ Recently, it has been reported that the risk for malignant melanoma among patients with systemic mastocytosis appeared higher than in the general population.¹¹ Mast cells would interact with melanocytes through the release of cytokines. But the direct connection with the MIA is unidentified at present. Further studies will be necessary to elucidate the effect of MIA with melanocytes from cutaneous mastocytosis.

The authors declare no conflict of interest.

REFERENCES

- 1 Valent P, Akin C, Escribano L, Födinger M, Hartmann K, Brockow K, et al. Standards and standardization in mastocytosis: consensus statements on diagnostic, treatment recommendations and response criteria. *Eur J Clin Invest.* 2007;37:435-53. PMID: 17537151.
- 2 Bosserhoff AK, Kaufmann M, Kaluza B, Bartke I, Zirngibl H, Hein R, et al. Melanoma-inhibiting activity, a novel serum marker for progression of malignant melanoma. *Cancer Res.* 1997;57:3149-53. PMID: 9242442.
- 3 Yoshida Y, Furumura M, Tahira M, Horie T, Yamamoto O. Serum biomarker in neurofibromatosis type 1. *J Dermatol Sci.* 2012;67:155-8. PMID: 22609162.
- 4 Bosserhoff AK, Küster H, Hein R. Elevated MIA levels in the serum of pregnant women and of children. *Clin Exp Dermatol.* 2004;29:628-9. PMID: 15550140.
- 5 Brockow K, Ring J. Update on diagnosis and treatment of mastocytosis. *Curr Allergy Asthma Rep.* 2011;11:292-9. PMID: 21523372.
- 6 Kushnir-Sukhov NM, Brittain E, Scott L, Metcalfe DD. Clinical correlates of blood serotonin levels in patients with mastocytosis. *Eur J Clin Invest.* 2008;38:953-8. PMID: 19021721.
- 7 Potier A, Lavigne C, Chappard D, Verret JL, Chevaillier A, Nicolie B, et al. Cutaneous manifestations in Hymenoptera and Diptera anaphylaxis: relationship with basal serum tryptase. *Clin Exp Allergy.* 2009;39:717-25. PMID: 19302252.
- 8 Büttner C, Henz BM, Welker P, Sepp NT, Grabbe J. Identification of activating c-kit mutations in adult-, but not in childhood-onset indolent mastocytosis: a possible explanation for divergent clinical behavior. *J Invest Dermatol.* 1998;111:1227-31. PMID: 9856847.
- 9 Poser I, Tatzel J, Kuphal S, Bosserhoff AK. Functional role of MIA in melanocytes and early development of melanoma. *Oncogene.* 2004;23:6115-24. PMID: 15208686.
- 10 Graf SA, Busch C, Bosserhoff AK, Besch R, Berking C. SOX10 Promotes Melanoma Cell Invasion by Regulating Melanoma Inhibitory activity. *J Invest Dermatol.* 2014 Mar 7. [Epub ahead of print]. PMID: 24608986.
- 11 Hägglund H, Sander B, Gülen T, Lindelöf B, Nilsson G. Increased Risk of Malignant Melanoma in Patients with Systemic Mastocytosis? *Acta Derm Venereol.* 2014 Jan 28. [Epub ahead of print]. PMID: 24473924.