

# Thoracoscopic Resection of an Anterior Mediastinal Bronchogenic Cyst

**Shinji Fujioka, Tomohiro Haruki, Yoshin Adachi, Ken Miwa, Yuji Taniguchi, Hiroshige Nakamura and Hisao Ito\***

*Division of Thoracic Surgery, Clinical Department of Surgery, Tottori University Hospital, Yonago 683-8504 and \*Division of Organ Pathology, Department of Microbiology and Pathology, School of Medicine, Tottori University Faculty of Medicine, Yonago 683-8503 Japan*

**We report a very rare case of anterior mediastinal bronchogenic cyst, successfully resected by thoracoscopic surgery. A 78-year-old female was noted as having an abnormal shadow on her chest X-ray during a routine medical checkup. Chest CT revealed a cystic tumor in the anterior mediastinum. A thymic cyst was suspected after a detailed examination and thoracoscopic surgery was performed. A cystic tumor containing yellowish-white mucus measuring 46 × 33 × 19 mm in size was successfully removed. Calcification was also observed in the cyst wall. Pathologically, the tumor was characterized by a ciliated columnar epithelial lining, and was subsequently diagnosed as a bronchogenic cyst. Although they may be rare, bronchogenic cysts should also be considered in the evaluation of cystic tumors in the anterior mediastinum.**

**Key words:** anterior mediastinum; bronchogenic cyst; thoracoscopic resection

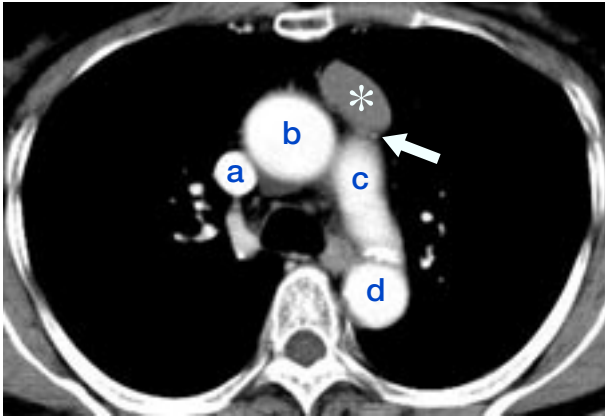
Bronchogenic cysts are rare mediastinal cystic tumors accounting for 4.5% to 5% of all mediastinal tumors (Martinod et al., 2000; Kori et al., 1993) and their occurrence in the anterior mediastinum is very rare. We describe a case of anterior mediastinal bronchogenic cyst, which was successfully removed by thoracoscopic surgery.

## Patient Report

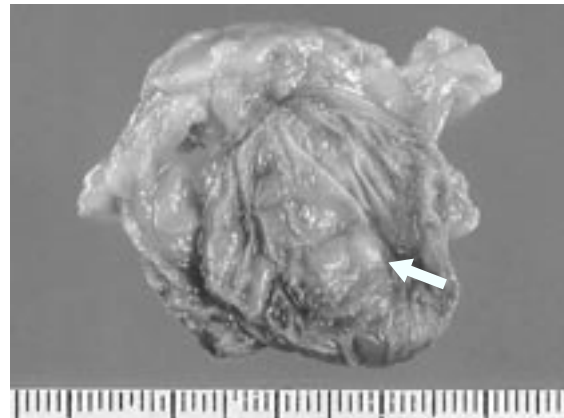
A 78-year-old female was noted as having an abnormal shadow on her chest X-ray during a routine medical checkup. She subsequently visited a neighborhood hospital where chest CT revealed no lesion at the site shown by the previous chest X-ray, but disclosed a tumor mass in the anterior mediastinum. She was referred to our department for evaluation and therapy. There were no subjective symptoms. She had had operations for colon

cancer and a ruptured cerebral aneurysm with subarachnoid hemorrhage eight years ago. No particular abnormalities were found in hematological or biochemical examinations. Chest CT at our hospital detected an oval tumor mass 30 × 20 mm in size with a clear boundary in the anterior mediastinum bounded posteriorly by the ascending aorta. The tumor showed no contrast enhancement but calcification was observed in part of the wall (Fig. 1). Chest MRI examination was not conducted because of the previous clipping surgery for cerebral aneurysm. The preoperative diagnosis was a thymic cyst and thoracoscopic resection was performed. The tumor was present in the anterior mediastinum, bordering on the anterior surface of the ascending aorta, and included the surrounding thymic fat. It was easily removed through a 4-port operation. Surgery took 56 min with a minimal amount of bleeding. After it was removed, the tumor was measured at 46 × 33 ×

Abbreviations: CT, computed tomography; MRI, magnetic resonance imaging; VATS, video-assisted thoracoscopic surgery



**Fig. 1.** Chest contrast CT. In the anterior of the ascending aorta (**b**), an oval tumor mass (\*) with a clear boundary is detected. There is no contrast enhancement in the tumor, and calcification is observed in part of the wall (arrow). **a:** superior vena cava, **b:** ascending aorta, **c:** aortic arch, **d:** descending aorta.

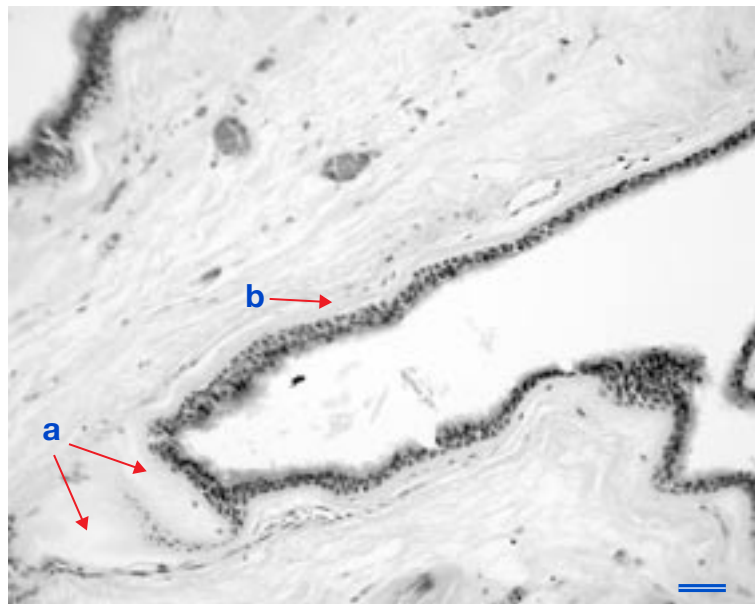


**Fig. 2.** Macroscopic appearance of the cut surface of the removed tumor, showing the internal surface of the tumor measuring  $46 \times 33 \times 19$  mm. Yellowish-white, slightly cloudy, viscous contents within the cyst have drained out. Calcification is observed in part of the wall (arrow).

19 mm and contained yellowish-white, slightly cloudy, viscous contents on the cut surface (Fig. 2). During pathological examination, the internal surface of the cyst was covered with ciliated columnar epithelial cells, and mucous glands, cartilage, and smooth muscles were observed in the cyst wall (Fig. 3). The tumor was diagnosed as a bronchogenic cyst and the postoperative course was good.

## Discussion

More than 90% of bronchogenic cysts occur in the mediastinum and lungs, mostly in the former (77%) (Zhang et al., 2003; St-Georges et al., 1991). Their occasional occurrence in the diaphragm, peritoneum or subcutaneous tissue



**Fig. 3.** Pathological findings of the resected tumor. The tumor is characterized by a bronchial epithelial lining and the presence of cartilage in its wall. The cartilage (**a**), smooth muscles (**b**) and mucous glands are also observed in the cyst wall (hematoxylin and eosin staining). Bar = 100  $\mu$ m.

has also been reported as ectopic bronchogenic cysts (Kim et al., 2001; Hamaguchi et al., 2002; Okada et al., 2006). Concerning the origin of ectopic bronchogenic cysts, two theories are widely accepted. The first theory is sequestration or budding of the tracheal primordia at the time of the development of the sternum. The second theory is the abnormal migration of the pinched-off tracheobronchial epithelium to the ectopic areas, prior to the complete fusion of the sternal mesenchymal bars (Kim et al., 2001). The present case may be explained by the second theory. Maier classifies bronchogenic cysts into five types based on the sites of occurrence: paratracheal (type I); tracheal bifurcation (type II); hilar (type III); paraesophageal (type IV) and others (type V) (Maier, 1948). Bronchogenic cysts of the anterior mediastinum are classified as type V. Their occurrence is most frequent in the middle mediastinum, including types I, II, and III, accounting for 40% of all mediastinal bronchogenic cysts (Hara et al., 2001).

Out of 68 cases of bronchogenic cysts appearing in areas other than the middle mediastinum, only 3 cases (3.4%) occurred in the anterior mediastinum (type V) (Kagotani et al., 1986). Our survey of previous Japanese cases of bronchogenic cysts revealed only 11 cases in the anterior mediastinum (Kagotani et al., 1986; Taniwaki et al., 1997; Takasuna et al., 1999; Takei, 2005). Thus, anterior mediastinal bronchogenic cysts are very rare.

Generally, CT findings of bronchogenic cysts show a higher density than water in most cases (75%), and contrast enhancement in the cyst wall (33%), although this may not always be typical (Hara et al., 2001). The chest CT in our case showed a higher density than water, but no contrast enhancement. T2-weighted MRI images often show significantly homogenous high signals. So MRI is useful for diagnosis of cystic tumors (Hara et al., 2001). Chest MRI was not conducted in our case because the patient had clipping surgery for a ruptured cerebral aneurysm 8 years previous.

The differential diagnosis of anterior mediastinal cystic tumors includes thymic cysts and mature cystic teratomas. Thymic cysts show a thin and translucent wall, and no contrast enhancement on chest CT. Mature cystic teratomas have distinct, sharply delineated walls which are often calcified and thickened (Rosai, 1996). Surgery is not always needed for asymptomatic cases of bronchogenic cysts. However, there is at least one report describing a cyst wall showing some malignant change into glandular cancer (Sullivan et al., 1999). Thus, thoracoscopic surgery has now been widely accepted for the treatment of bronchogenic cysts. Although thymic cysts are most frequent among cystic tumors in the anterior mediastinum, surgeons should consider the possibility of bronchogenic cysts in the differentiation of those tumors.

## References

- 1 Hamaguchi N, Ohnishi K, Kaihotho N, Fujishima N, Tamaki M, Ichikawa H, et al. Subdiaphragmatic bronchogenic cyst in the left crus of diaphragm: report of a case. *Kyobu Geka* 2002;55:523–525.
- 2 Hara M, Itoh M, Ogino H, Nakayama J, Satake M, Sato Y, et al. [Mediastinal cystic lesions: CT and MRI findings.] *Nippon Igaku Hoshasen Gakkai Zasshi* 2001;61:147–155 (in Japanese with English abstract).
- 3 Kagotani K, Horii A, Watase M, Yamagami S, Shibata N, Aikawa T, et al. A case report of posterior mediastinal bronchial cyst. *Kyobu Geka* 1986;39:909–912.
- 4 Kori Y, Sano Y, Aoe M, Okabe K, Shimizu N. Thirty-Eight operative cases of mediastinal cyst. *Kyobu Geka* 1993;46:1008–1012.
- 5 Maier HC. Bronchogenic cyst of the mediastinum. *Ann Surg* 1948;127:476.
- 6 Martinod E, Pons F, Azorin J, Mouroux J, Dahan M, Faillon JM, et al. Thoroscopic excision of mediastinal bronchogenic cyst: results in 20 cases. *Ann Thorac Surg* 2000;69:1525–1528.
- 7 Kim NR, Kim HH, Suh YL. Cutaneous bronchogenic cyst of the abdominal wall. *Pathol Int* 2001;51:970–973.
- 8 Okada S, Ishida H, Yamada N, Konishi F. A case of intradiaphragmatic bronchogenic cyst successfully resected by VATS. *Nippon Rinsho Geka Gakkai Zasshi* 2006;67:1001–1004 (in Japanese with English abstract).

- 9 Rosai J. Ackerman's surgical pathology. 8th ed. St. Louis: Mosby; 1996. p. 435–491.
- 10 St-Georges R, Deslauriers J, Duranceau A, Vaillancourt R, Deschamps C, Beauchamp G, et al. Clinical spectrum of bronchogenic cysts of the mediastinum and lung in the adult. *Ann Thorac Surg* 1991;52:6–13.
- 11 Sullivan SM, Okada S, Kudo M, Ebihara Y. A retroperitoneal bronchogenic cyst with malignant change. *Pathol Int* 1999;49: 338–341.
- 12 Takasuna K, Yamanda T, Makiuchi A, Kondoh R, Numanami H, Machida E, et al. Two cases of the bronchial cyst located in the anterior mediastinum. *Kyobu Geka* 1999;52:959–61.
- 13 Takei K, Nakamura K, Takahashi O. A case of double mediastinum bronchogenic cysts. *Nippon Kokyoku Geka Gakkai Zasshi* 2005;19:828–832 (in Japanese with English abstract).
- 14 Taniwaki S, Tanaka H, Hunato Y, Hanaki H, Takeyama S, Kawakami M. Thymic cyst resembling a bronchogenic cyst. *Nippon Kyobu Shikkan Gakkai Zasshi* 1997;35:201–204.
- 15 Zhang Y, Yang SR, Cheng DU, Guan J. [Clinical and pathological features of congenital bronchial cyst.] *Zhonghua Jie He He Hu Xi Za Zhi* 2003;26: 619–22 (in Chinese).

*Received March 22, 2007; accepted May 29, 2007*

*Corresponding author: Shinji Fujioka, MD*