

Expression of phospho-Akt and PTEN Proteins Predicts the Survival of Patients with Pancreatic Cancer

Yoshimi Ozaki-Ohgami, Akemi Iwamoto, Shizue Yoshioka, Shigeru Tatebe, Yasuaki Hirooka and Masahide Ikeguchi

Division of Surgical Oncology, Department of Surgery, School of Medicine, Tottori University Faculty of Medicine, Yonago 683-8504 Japan

The phosphatidylinositol-3 kinase (PI3K)-Akt signaling pathway is known to protect a variety of cells from apoptosis. Phospho-Akt (p-Akt) can facilitate cell survival and inactivating pro-apoptotic proteins. The phosphatase and tensin homologue deleted on chromosome ten (PTEN) is a natural biological inhibitor of p-Akt in the PI3K-Akt pathway. The relationship between the expressions of p-Akt and PTEN and pancreatic cancer is unknown. Here, we designed a study to clarify the prognostic significance of p-Akt and PTEN expression in patients with pancreatic cancer. Immunohistochemical analysis of p-Akt and PTEN protein was performed on 51 specimens of pancreatic cancer. The expression of p-Akt was detected in 32 patients (62.7%). The expression of p-Akt was frequently detected in patients with advanced stage pancreatic cancer ($P = 0.0233$). Patients with p-Akt-positive tumors had significantly worse prognoses than those with p-Akt-negative tumors (overall survival; 11.3% versus 25.7%). The expression of PTEN was detected in 26 patients (51.0%). Patients with PTEN-positive tumors had significantly better prognoses than those with PTEN-negative tumors (overall survival; 29.9% versus 0%). Patients with p-Akt-positive and PTEN-negative tumors had significantly worse prognoses than those with p-Akt-negative and PTEN-positive tumors (overall survival; 0% versus 39.1%). Multivariate analysis revealed that expression of p-Akt was an independent prognostic factor as well as arterial invasion and lymph node metastasis. The expression of p-Akt and PTEN proteins determined by immunohistochemistry may be a new method for predicting the prognosis of patients with pancreatic cancer.

Key words: immunohistochemistry; pancreatic cancer; phosphatase and tensin homologue deleted on chromosome ten; phosphorylated-Akt

Patients with pancreatic cancer usually have poor prognoses because of high malignancy and resistance to most available chemotherapeutic agents due to pancreatic cancer's resistance to apoptosis (Bardeesy and DePinho, 2002; Heinemann, 2002; Shi et al., 2002). In addition, it is difficult to cure pancreatic cancer through surgical resec-

tion because it easily invades adjacent tissue. Therefore, a new therapeutic modality needs to be investigated for treating pancreatic cancer. Enhanced understanding of the signaling mechanisms that regulate pancreatic cancer cell growth may provide important insights into more effective therapeutic strategies.

Abbreviations: p-Akt, phosphorylated-Akt; PI3K, phosphatidylinositol-3 kinase; PTEN, phosphatase and tensin homologue deleted on chromosome ten

Akt consists of a family of highly conserved serine/threonine kinases. These kinases are activated in response to a wide variety of growth factors through phosphatidylinositol-3 kinase (PI3K). Phosphorylation of Akt, which is activated Akt, is promoted by phosphatidylinositides converted by PI3K products. Phosphorylated Akt (p-Akt) can facilitate cell survival and inactivate pro-apoptotic proteins such as Bad and caspase-9 (Datta et al., 1997; Cardone et al., 1998). Recently, p-Akt has been demonstrated as a major mediator of survival signals in a variety of cells including cancer cells (Tang et al., 2001). To date, there have been a few studies on the incidence of Akt activation in various tumors using archived pathologic specimens. In colon cancer, Akt activation was observed in patients in advanced clinicopathological stages of the disease (Itoh et al., 2002). In breast cancer, Akt activation was frequently observed while a worse prognosis was predicted in endocrine-treated patients (Perez-Tenorio and Stal, 2002). Phosphorylated-Akt by PI3K plays an important role in the biological behavior of pancreatic cancer and its inhibition may provide a means of treatment against pancreatic cancer (Cheng et al., 1996; Franke et al., 1995; Hinemann, 2002). However, there have been few studies on p-Akt in patients with pancreatic cancer. The phosphatase and tensin homologue deleted on chromosome ten (PTEN) is a tumor suppressor protein that dephosphorylates inositol phospholipid intermediates of the PI3K pathway, inhibiting activation of downstream targets including Akt (Leslie and Downes, 2002). It has been suggested that the loss of PTEN activity causes enhanced cell proliferation, decreased apoptosis and increased tumor angiogenesis (Stambolic et al., 1998; Zhong et al., 2000). Several groups have reported loss of heterozygosity, mutation or deletion of the gene in different cancers, including glioblastoma, prostate, lung and breast carcinomas. Altered expression of PTEN has also been detected in various precancerous lesions (Li et al., 1997; McMenamin et al., 1999; Mutter et al., 2000; Perren et al., 1999). However, there have been few studies on the role of PTEN as a suppressor of tumor growth

in patients with pancreatic cancer.

The relationship between p-Akt and PTEN expression in human pancreatic cancer is not yet fully understood. Expression of p-Akt and PTEN in pancreatic cancer has not been shown to predict tumor malignancy or prognosis. We hypothesize that expression of p-Akt and PTEN may be a novel indicator of advanced stage pancreatic cancer or patient prognosis. In the present study, expression of p-Akt and PTEN was immunohistochemically examined in 51 patients with pancreatic cancer, and the correlation between expression of p-Akt and PTEN and clinicopathological features was studied.

Materials and Methods

Patients

Fifty-one patients who underwent curative resection of primary pancreatic cancer from October 1984 to September 2001 were selected for the study. Patient age ranged from 39 to 80 years (average 65.2 years); 38 were male and 13 female. The clinicopathological findings were determined according to established Tumor-Node-Metastasis criteria (Sobin and Wittekind, 2002). Surgically resected specimens were macroscopically examined to determine tumor location, size and invasion of blood vessels. Tissue samples were fixed in 10% formalin and processed by paraffin embedding. Histological sections were cut, stained with hematoxylin and eosin and evaluated by pathologists to determine the degree of histological differentiation, existence of lymph node metastasis and invasion of blood vessels. The patients' progress was followed up until February 2002. The follow-up periods for survivors ranged from 2 to 127 months (median, 22.8 months) after surgery.

Immunohistochemistry

For immunohistochemical analysis, the streptavidin-biotin method (Histofine SAB-PO kit;

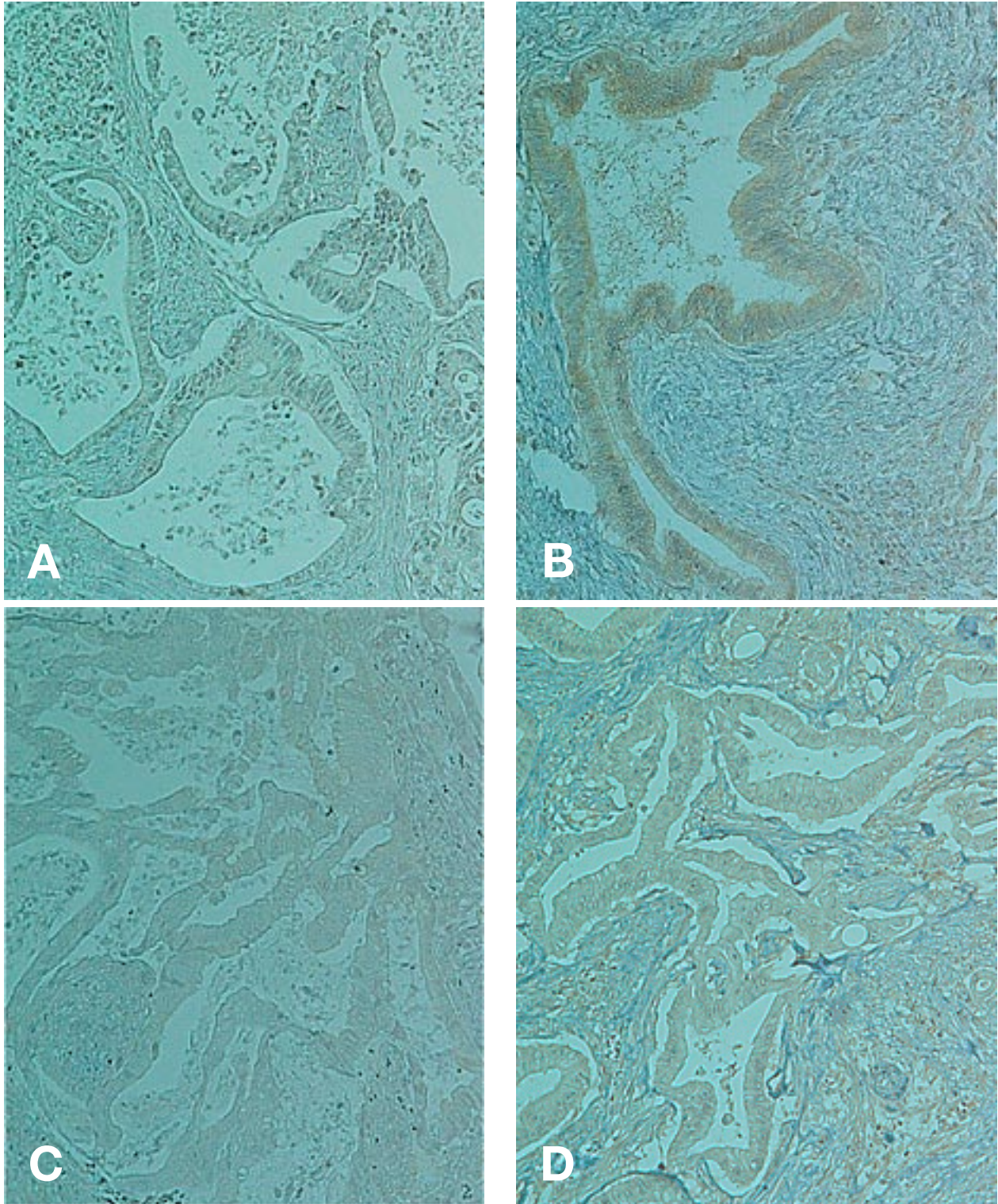


Fig. 1. Typical results of p-Akt and PTEN immunohistochemistry. **A:** p-Akt-negative cases. **B:** p-Akt-positive cases. **C:** PTEN-negative cases. **D:** PTEN-positive cases (original magnification, $\times 100$).

Nichirei, Tokyo, Japan) was used for formalin-fixed and paraffin-embedded specimens. Tissue

sections were dewaxed in xylene, rehydrated in ethanol, and autoclaved at 120°C for 30 min in

Target Retrieval Solution (DAKO, Carpinteria, CA) for retrieval of antigens. Endogenous peroxidase was blocked with 0.3% hydrogen peroxide in methanol for 20 min. Tissue sections were washed three times with phosphate-buffered saline (PBS) and pre-blocked for 60 min with 10% goat serum. After washing with PBS, the samples were incubated at 4°C for 48 h with the following primary antibodies: polyclonal antibodies rose against p-Akt (Ser 473) (diluted 1:100; Cell Signaling Technology, Beverly, MA) and PTEN (diluted 1:100; Upstate Cell Signaling Solutions, Charlottesville, VA). Sections were washed three times in PBS and incubated with the secondary antibody, anti-rabbit immunoglobulin (IgG + IgA + IgM) conjugated with biotin (Nichirei) for 60 min, followed by incubation with a streptavidin-peroxidase complex (Nichirei) for 60 min. After three additional washes in PBS, diaminobenzidine tetrahydrochloride working solution was applied. Finally, the slides were counterstained with hematoxylin.

All immunostained sections were evaluated in a blinded manner with no knowledge of clinical and pathological factors. p-Akt and PTEN expression was not detected in the non-neoplastic region of the pancreas. The intensity of staining seen in different areas of the same slide was analyzed using previously reported criteria (Malik et al., 2002). The intensity is designated as negative when no tumor cells are stained, weak when 10–20% of tumor cells are stained, moderate when 20–50% of tumor cells are stained, and strong

when > 50% of tumor cells are stained. The staining pattern was classified as follows: when more than $\geq 50\%$ of the tumor cells showed positive staining, labeling was considered positive, and when $< 50\%$ of the tumor cells showed positive staining, labeling was considered negative.

Statistical analysis

Statistical analysis included the standard chi-square test and Mann-Whitney U test. The survival rates were estimated by the Kaplan-Meier method, and statistical analysis was carried out by the log-rank test for equality of the survival curves. In multivariate analysis, the influence of each variable on survival was assessed by the Cox proportional hazards model and a stepwise procedure (StatView 5.0; Abacus Concepts Berkeley, CA). Statistical significance was considered with $P < 0.05$.

Results

Immunohistochemistry showed that 32 (62.7%) of the 51 tumors demonstrated p-Akt-positive expression, and 26 (51%) demonstrated PTEN-positive expression (Table 1). The typical pattern of p-Akt and PTEN staining included both cytoplasmic and nuclear immunostaining (Fig. 1).

A tendency towards some close correlation between p-Akt and PTEN expression was noticeable, but there was no significant relationship between p-Akt and PTEN expression ($P = 0.0549$; Table 1). The correlation between p-Akt or PTEN expression and clinicopathological factors is shown in Table 2. p-Akt expression showed no correlations with age, gender, histology, venous invasion or lymph node metastasis, whereas it was significantly associated with tumor size, arterial invasion and pathological stage. These data suggest that p-Akt expression was correlated with tumor progression in pancreatic cancer. On the other hand, PTEN expression showed no correlation with age, tumor size, gender, histology, venous

Table 1. Correlations between p-Akt and PTEN expressions

	PTEN		Total
	Negative	Positive	
p-Akt-negative	6	13	19 (37.3%)
p-Akt-positive	19	13	32 (62.7%)
Total	25 (49%)	26 (51%)	51 (100%)

There was a tendency towards a close correlation between p-Akt and PTEN expression, but the relationship between p-Akt and PTEN expression was not significant ($P = 0.0549$).

Table 2. Correlation between expressions of p-Akt or PTEN and clinicopathological factors in 51 patients with pancreatic cancer

Variable	p-Akt			PTEN		
	Positive (%)	Negative (%)	<i>P</i> value	Positive (%)	Negative (%)	<i>P</i> value
Age† (year)						
< 65	11 (34.4)	9 (47.4)	NS	11 (42.3)	9 (36.0)	NS
≥ 65	21 (67.4)	10 (52.6)		15 (57.7)	16 (64.9)	
Tumor size‡ (cm)						
< 4.0	13 (44.8)	14 (73.7)	0.0487	14 (56.0)	13 (56.5)	NS
≥ 4.0	16 (55.2)	5 (26.3)		11 (44.0)	10 (43.5)	
Gender						
Male	25 (78.1)	13 (64.8)	NS	18 (69.2)	20 (80.0)	NS
Female	7 (21.9)	6 (31.6)		8 (30.8)	5 (20.0)	
Histology: Invasive ductal carcinoma						
Good	10 (31.3)	7 (36.8)	NS	8 (30.8)	9 (36.0)	NS
Moderate	20 (62.5)	9 (47.4)		14 (53.8)	15 (60.0)	
Poor	2 (6.3)	3 (15.8)		4 (15.4)	1 (4.0)	
Arterial invasion						
Positive	15 (46.9)	3 (15.8)	0.0247	5 (19.2)	13 (52.0)	0.0144
Negative	17 (53.1)	16 (84.2)		21 (80.8)	12 (48.0)	
Venous invasion						
Positive	14 (43.8)	5 (26.3)	NS	7 (26.9)	12 (48.0)	NS
Negative	18 (56.3)	14 (73.7)		19 (73.1)	13 (52.0)	
Lymph node metastasis						
Positive	23 (71.9)	14 (73.7)	NS	16 (61.5)	21 (84.0)	NS
Negative	9 (28.1)	5 (26.3)		10 (38.5)	4 (16.0)	
Stage (pTNM)						
I	1 (3.1)	0 (0.0)	0.0233	1 (3.8)	0 (0.0)	NS
II	4 (12.5)	0 (0.0)		1 (3.8)	3 (12.0)	
III	5 (15.6)	11 (57.9)		11 (42.3)	5 (20.0)	
IV	22 (68.8)	8 (42.1)		13 (50.0)	17 (68.0)	

† Mean ± SD, 65.2 ± 8.0 years.

‡ Mean ± SD, 3.9 ± 1.3 cm.

NS, not significant; pTNM, pathological tumor-node-metastasis.

p-Akt-negative expression was more frequently detected in smaller size tumors and in none of the cases with arterial invasion. p-Akt-positive expression was more frequently detected in advanced histological stage tumors. PTEN-positive expression was detected significantly more frequently in patients with no arterial invasion.

invasion, lymph node metastasis or pathological stage, whereas it was significantly associated with arterial invasion ($P = 0.0144$).

Postoperative survival curves for patients with pancreatic cancer according to p-Akt and PTEN expression are shown in Figs. 2 and 3, respectively. The estimated 5-year survival rate for patients with negative or positive p-Akt expression was 25.7 and 11.3%, respectively. Patients with p-Akt-positive tumors had significantly poorer prognoses than those with p-Akt-negative tumors ($P = 0.0132$; Fig. 2). The estimated 5-year survival rate for patients with negative and positive PTEN expression was 0 and 29.9%, respectively.

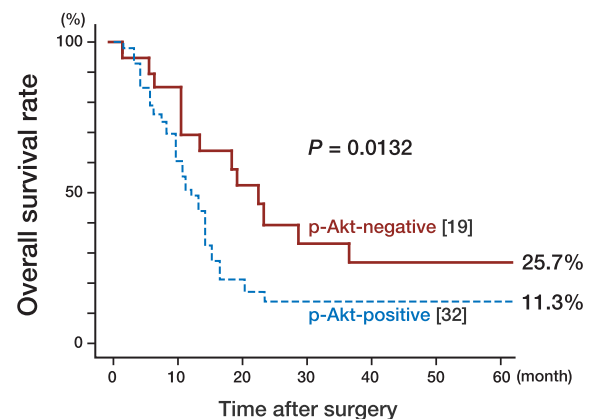


Fig. 2. Post-operative survival curves of patients with pancreatic cancer according to expression of p-Akt. Patients with positive p-Akt tumors had significantly worse prognoses than those with p-Akt-negative tumors ($P = 0.0132$). [], number of cases.

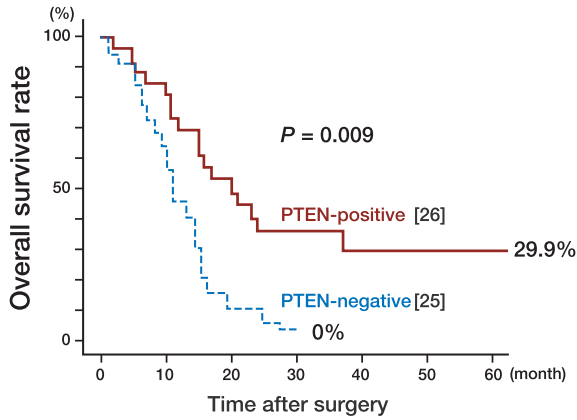


Fig. 3. Postoperative survival curves of patients with pancreatic cancer according to expression of PTEN. Patients with PTEN-negative tumors had significantly worse prognoses than those with PTEN-positive tumors ($P = 0.009$). [], number of cases.

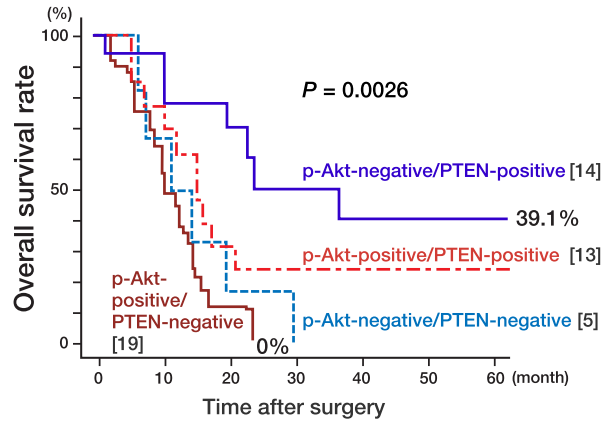


Fig. 4. Postoperative survival curves of patients with pancreatic cancer according to expression of p-Akt and PTEN. Patients with p-Akt-positive besides and PTEN-negative tumors had significantly worse prognoses than those with p-Akt-negative and PTEN-positive tumors ($P = 0.0026$). [], number of cases.

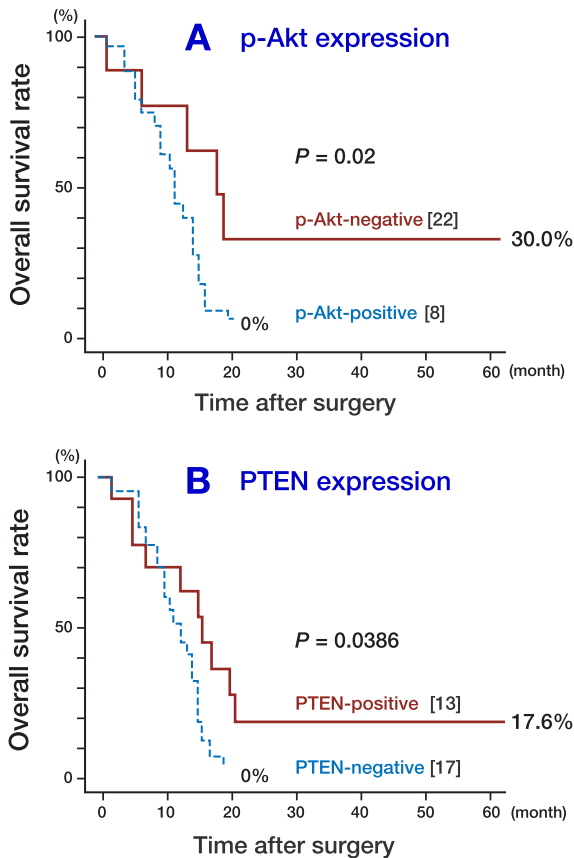


Fig. 5. Postoperative survival curves of patients with pancreatic cancer in stage IV. [], number of cases.
A: Patients with p-Akt-positive tumors had a significantly shorter survival time than those with p-Akt-negative tumors ($P = 0.02$).
B: Patients with PTEN-positive tumors had a significantly longer survival time than those with PTEN-negative tumors ($P = 0.0386$).

Patients with PTEN-positive tumors had significantly better prognoses than those with PTEN-negative tumors ($P = 0.009$; Fig. 3). Patients with p-Akt-negative and PTEN-positive tumors had significantly better prognoses than those with the p-Akt-positive and PTEN-negative tumors (39.1% versus 0%, respectively; $P = 0.0026$; Fig. 4).

In 30 patients with pathological stage IV tumors, those with p-Akt-positive tumors had a significantly shorter survival time than those with p-Akt-negative tumors ($P = 0.02$; Fig. 5A), and patients with PTEN-positive tumors had a significantly longer survival time than those with PTEN-negative tumors ($P = 0.0386$; Fig. 5B). These results suggest that expression of p-Akt and PTEN can predict the prognoses of patients with pancreatic cancer.

Multivariate analysis by the Cox proportional hazards model and a stepwise procedure was performed to determine the significance of the prognoses of patients with pancreatic cancer.

Covariates were p-Akt expression, PTEN expression, histology, venous invasion, arterial invasion, lymphatic vessel invasion and pathological stage. p-Akt expression, arterial invasion and lymph node metastasis were found to be independent prognostic factors in patients with pancreatic cancer (Table 3).

Discussion

The PI3K-Akt signaling pathway is known to transmit survival signals and to protect a variety of cells from apoptosis. Akt plays a critical role in controlling the balance between cell survival and apoptosis (Alessi et al., 1997). It has also been reported that Akt plays an important role in cell survival when cells are exposed to different apoptotic stimuli, such as growth factor withdrawal, ultraviolet radiation, matrix detachment, cell cycle discordance and DNA damage (Burnet et al., 1999; Camp et al., 2004). Phosphorylation of Akt is promoted by phosphatidylinositides converted by PI3K products. Therefore, when phosphorylation of Akt is inhibited, apoptosis can be induced (Balendran et al., 1999; Brognard et al., 2001). Inactivation of PI3K using a specific inhibitor leads to dephosphorylation of Akt at Ser473, consequently causing translocation of Akt to the nucleus, where it is believed to regulate the transcription of genes mediating cell survival or apoptosis (Cardone et al., 1998). Therefore, it is supposed that the PI3K-Akt pathway plays a significant role in malignant cells. There is increasing evidence that Akt is activated in many different cancers and that this signaling pathway confers a potent survival signal (West et al., 2002). The tumor suppression gene PTEN is a natural biological inhibitor of Akt in cell survival signals. In the present study, we have demonstrated by immunohistochemistry the frequent occurrence of p-AKT and PTEN expression in surgically resected pancreatic cancers. In addition, our results reveal that p-Akt expression is a sign of poor prognosis in patients with pancreatic

Table 3. Multivariate analysis of prognostic factors by the Cox proportion hazard model

	Hazard ratio	95% CI	P value
p-Akt expression†	2.294	1.078– 4.878	0.0201
Arterial invasion†	6.279	2.902–13.581	< 0.0001
Lymph node metastasis†	4.531	1.962–10.465	0.0005

† Positive or negative.

CI, confidence interval.

p-Akt Expression, arterial invasion and lymph node metastasis are independent prognostic factors in patients with pancreatic cancer.

cancer. Additional investigation is necessary to clarify the mechanism that controls p-Akt expression and activation. The inhibition of p-Akt may be a molecular target for the treatment of pancreatic cancer.

PTEN negatively regulates the PI3-Akt pathway and its mutation is associated with an aggressive tumor phenotype (Di Cristofano and Pandolfi, 2000). The decreased expression of PTEN in pancreatic cancer occurs at the mRNA and protein levels, and deletions or mutations are not frequently observed (Ebert et al., 2002). Although it seems clear that the main role of PTEN is to regulate the PI3K-Akt pathway, many important issues remain unresolved in pancreatic cancer. In the present study, we analyzed the relationship between p-Akt and PTEN expression and prognosis of patients with pancreatic cancer. The present immunohistochemical study shows a significant association between positive PTEN expression and good prognosis. Our data also demonstrate a tendency towards a close correlation between p-Akt and PTEN expression ($P = 0.00549$). Pancreatic cancer patients with p-Akt-negative and PTEN-positive tumors had significantly better prognoses than those with p-Akt-positive and PTEN-negative tumors. These results suggest that increased expression of PTEN inhibits phosphorylation of Akt and subsequently the ability of Akt to promote pancreatic cancer invasion and resistance to apoptosis. Although additional studies on the mechanism of PTEN are

needed, increasing the expression of PTEN protein may contribute to a new, effective treatment for pancreatic cancer.

In conclusion, we have found that a high expression level of p-Akt protein is significantly correlated with poor prognosis, and that high expression of PTEN protein is significantly correlated with good prognoses in patients with pancreatic cancer. Furthermore, it has been suggested that patients with negative expression of p-Akt and positive expression of PTEN have good prognoses. Therefore, the expression of p-Akt and PTEN protein determined by immunohistochemistry may be a new method for predicting prognoses in patients with pancreatic cancer. It may be that p-Akt and PTEN expression are novel targets in the search for effective therapeutic options for pancreatic cancer.

Acknowledgments: We thank Dr. Kiyoshi Kishi (Division of Surgery, Tottori Prefectural Central Hospital, Japan) for providing surgically resected specimens from patients with pancreatic cancer.

References

- Alessi DR, James SR, Downes CP, Holmes AB, Gaffney PR, Reese CB, et al. Characterization of a 3-phosphoinositide-dependent protein kinase which phosphorylates and activates protein kinase Balph. *Curr Biol* 1997;7:261–269.
- Balendran A, Casamayor A, Deak M, Paterson A, Gaffney P, Currie R, et al. PDK1 acquires PDK2 activity in the presence of a synthetic peptide derived from the carboxyl terminus of PRK2. *Curr Biol* 1999;9:393–404.
- Bardeesy N, DePinho RA. Pancreatic cancer biology and genetics. *Nat Rev Cancer* 2002;2:897–909.
- Brogna J, Clark AS, Ni Y, Dennis PA. Akt/protein kinase B is constitutively active in non-small cell lung cancer cells and promotes cellular survival and resistance to chemotherapy and radiation. *Cancer Res* 2001;61:3986–3997.
- Bondar VM, Sweeney-Gotsch B, Andreeff M, Mills GB, McConkey DJ. Inhibition of the phosphatidylinositol 3'-kinase-AKT pathway induces apoptosis in pancreatic carcinoma cells in vivo and in vitro. *Mol Cancer Ther* 2002;12:989–997.
- Burnet A, Bonni A, Zigmund MJ, Lin MZ, Juo P, Hu LS, et al. Akt promotes cell survival by phosphorylating and inhibiting a Forkhead transcription factor. *Cell* 1999;96:857–868.
- Cardone MH, Roy N, Stennicke HR, Salvesen GS, Franke TF, Stanbridge E, et al. Regulation of cell death protease caspase-9 by phosphorylation. *Science* 1998;282:1318–1321.
- Camp ER, Li J, Minnich DJ, Brank A, Moldawer LL, MacKay SL, et al. Inducible nuclear factor-kap-paB activation contributes to chemotherapy resistance in gastric cancer. *J Am Coll Surg* 2004;199:249–258.
- Cheng JQ, Ruggeri B, Klein WM, Sonoda G, Altomare DA, Watson DK, et al. Amplification of AKT2 in human pancreatic cells and inhibition of AKT2 expression and tumorigenicity by antisense RNA. *Proc Natl Acad Sci* 1996;93:3636–3641.
- Datta SR, Dudek H, Tao X, Masters S, Fu H, Gotoh Y, et al. Akt phosphorylation of BAD couples survival signals to the cell-intrinsic death machinery. *Cell* 1997;91:231–241.
- Di Cristofano A, Pandolfi PP. The multiple roles of PTEN in tumor suppression. *Cell* 2000;100:387–390.
- Ebert MP, Fei G, Schandl L, Mawin C, Dietzmann K, Herrera P, et al. Reduced PTEN expression in the pancreas overexpressing transforming growth factor-beta 1. *Br J Cancer* 2002;86:257–262.
- Franke TF, Yang SI, Chan TO, Datta K, Kazluskas A, Morrison DK, et al. The protein kinase encoded by the Akt proto-oncogene is a target of the PDGF-activated phosphatidylinositol 3-kinase. *Cell* 1995;81:727–736.
- Hinemann V. Present and future treatment of pancreatic cancer. *Semin Oncol* 2002;29:23–31.
- Itoh N, Semba S, Itoh M, Takeda H, Kawata S, Yamakawa M. Phosphorylation of Akt/PKB is required for suppression of cancer cell apoptosis and tumor progression in human colorectal carcinoma. *Cancer* 2002;94:3127–3134.
- Leslie NR, Downes CP. PTEN: The down side of PI3-kinase signaling. *Cell Signal* 2002;14:285–295.
- Li J, Yen C, Liaw D, Podsypanina K, Bose S, Wang SI, et al. PTEN, a putative protein tyrosine phosphatase gene mutated in human brain, breast, and prostate cancer. *Science* 1997;275:1943–1947.
- Malik SN, Brattain M, Ghosh PM, Troyer DA, Prihoda T, Bedolla R, et al. Immunohistochemical demonstration of Phospho-Akt in high Gleason grade prostate cancer. *Clin Cancer Res* 2002;8:1168–1171.
- McMenamin ME, Soung P, Perera S, Kaplan I, Loda M, Selers WR. Loss of PTEN expression in paraffin-embedded primary prostate cancer correlates with high Gleason score and advanced stage. *Cancer* 1999;89:4291–4296.
- Mutter GL, Lin MC, Fitzgerald JT, Kum JB, Baak JP, Lees JA, et al. Altered PTEN expression as a di-

- agnostic marker for the earliest endometrial precancers. *J Natl Cancer Inst* 2000;92:924–930.
- 21 Perez-Tenorio G, Stal O. Activation of Akt/PKB in breast cancer predicts a worse outcome among endocrine treated patients. *Br J Cancer* 2002;86:540–545.
- 22 Perren A, Wenig LP, Boag AH, Ziebold U, Thakore K, Dahia PL, et al. Immunohistochemical evidence of loss of PTEN expression in primary ductal adenocarcinomas of the breast. *Am J Pathol* 1999;155:1253–1260.
- 23 Shi X, Liu S, Kleeff J, Friess H, Buchler MW. Acquired resistance of pancreatic cancer cell towards 5-Fluorouracil and gemcitabine is associated with expression of apoptosis-regulation genes. *Oncology* 2002;62:354–362.
- 24 Sobin LH, Wittekind Ch. TNM classification of malignant tumors (6ed.). New York: John Wiley & Sons; 2002. p. 93–96.
- 25 Stambolic V, Suzuki A, de la Pompa JL, Brothers GM, Mirtsos C, Sasaki T, et al. Negative regulation of PKB/Akt-dependent cell survival by the tumor suppressor PTEN. *Cell* 1998;95:29–39.
- 26 Tang D, Okada H, Ruland J, Liu L, Stambolic V, Mark TW, et al. Akt is activated in response to an apoptotic signal. *J Biol Chem* 2001;276:30461–30466.
- 27 West KA, Sianna-Castillo S, Dennis PA. Activation of the PI3K/Akt pathway and chemotherapeutic resistance. *Drug Resist Update* 2002;5:234–248.
- 28 Zhong H, Chiles K, Feldser D, Laughner E, Hanrahan C, Georgescu MM, et al. Modulation of hypoxia-inducible factor 1 alpha expression by the epidermal growth factor/phosphatidylinositol 3-kinase/PTEN/AKT/FRAP pathway in human prostate cancer cells: implications for tumor angiogenesis and therapeutics. *Cancer Res* 2000;60:1541–1545.

*Received December 12, 2005;
accepted December 22, 2005*

Corresponding author: Yoshimi Ozaki-Ohgami