

A New X-Linked Mental Retardation Syndrome with Diplegia and Delayed Myelination

Hiroaki Ehara, Kyoichi Ohtani*, Toshiyuki Yamamoto†, Kousaku Ohno‡, Kenzo Takeshita§, Yonehiro Kanemura¶ and Mami Yamasaki¶¶

*Department of Early Childhood Education and Care, Kurashiki City College, Kurashiki 711-0937, *Department of Pediatrics, Chizu Municipal Hospital, Chizu 689-1402, †Kanagawa Children's Medical Center, Yokohama 232-8555, ‡Department of Child Neurology, Institute of Neurological Sciences, Tottori University Faculty of Medicine, Yonago 683-8504, §Daiichi Welfare University, Dazaifu 818-0194 and ¶¶Institute for Clinical Research and Department of Neurosurgery, Osaka National Hospital, National Hospital Organization, Osaka 540-0006 Japan*

We report three boys (4, 6 and 8 years old) in a Japanese family with X-linked (XL) recessive severe mental retardation (MR), rigidospastic diplegia, mild athetotic movement of the upper limbs, delayed myelination and poor weight gain. Neurological manifestations were non-progressive. No deterioration of development, convulsion, cerebellar signs, dysarthria, pseudobulbar signs, or minor anomalies including facial dysmorphism or macro-orchidism were found. Ocular fundus was normal. The patients' mothers and one grandmother were clinically normal. Blood chemistry was within normal limits. Serum anti-human T-cell leukemia virus-I antibody titer was negative. Levels of plasma amino acids and serum very long chain fatty acids, and lysosomal enzyme activities from leukocytes were normal. Brain magnetic resonance imaging scans showed delayed myelination. Fragile X (FRAXA), fragile XE (FRAXE), proteolipid protein and L1 cell adhesion molecule (LICAM) genes were normal. These findings were not consistent with previously reported 13 XLMR syndromes with paralysis. We conclude that this condition is a distinct and previously undescribed XLMR syndrome.

Key words: L1 cell adhesion molecule; myelination delay; proteolipid protein; spastic diplegia; X-linked mental retardation syndrome

The frequency of mental retardation (MR) is estimated to be 1 to 3% according to WHO criteria (intelligence quotient less than 70) (Roeleveld et al., 1997), and X-linked mental retardation (XLMR) accounts for a quarter of all MR in males (Turner and Opitz, 1980). Significant progress has been made in research in the XLMR field (Lubs et al., 1999; Cabezas et al., 1999; Hamel et al., 2000; Chiurazzi et al., 2004), and a number of XLMR genes have been mapped and cloned recently. We report on three patients in a Japanese

family with XLMR associated with rigidospastic diplegia, mild athetotic movement of the upper limbs, delayed myelination and poor weight gain, as a possible previously undescribed syndrome.

Patients and Methods

Clinical reports

The pedigree is given in Fig. 1. Two mothers (II-5

Abbreviations: DQ, developmental quotient; FRAXA, fragile X; FRAXE, fragile XE; LICAM, L1 cell adhesion molecule; MR, mental retardation; MRI, magnetic resonance imaging; OFC, occipito-frontal circumference; SSCP, single strand conformation polymorphism; XL, X-linked

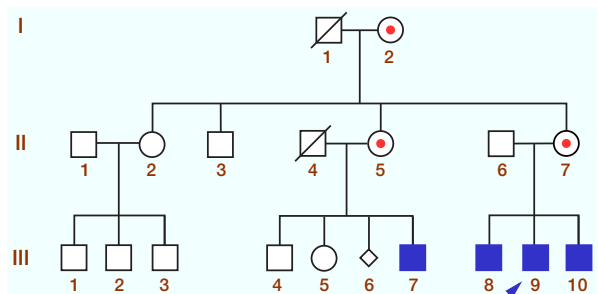


Fig. 1. Pedigree of the family. ■, affected male; ●, carrier female.

and 7) and one grandmother (I-2) were clinically normal.

Patient 1 (III-7)

Patient 1 was born at 40 weeks of gestation with a birth weight of 3490 g after an uncomplicated pregnancy to healthy, nonconsanguineous parents (mother, age 35, father 43). His Apgar score was 10. On day 6, phototherapy was carried out for 24 h since the serum total bilirubin level reached 337 $\mu\text{mol/L}$. He had controlled head movements at 3 months of age. Poor weight gain (6230 g) was noted at 5 months of age. He rolled over at 6 months of age. Hypertone of the lower extremities, developmental delay and poor weight gain (6580 g) were noted at 8 months of age at a general hospital. Delay of myelination at the 5-month level was also noticed on brain magnetic resonance imaging (MRI).

He was admitted to Tottori University Hospital for further examination at 11 months of age. His height was 74.0 cm (mean), weight 6.97 kg (-2.3 SD) and occipito-frontal circumference (OFC) 44.5 cm (-1.0 SD) on admission. His developmental quotient (DQ) was about 50. Other clinical and laboratory findings are summarized in Table 1. Motor nerve conduction velocity of the right median nerve, auditory brainstem responses, visual evoked potentials and electrically elicited blink reflex were normal. Latency of N20 of short-latency evoked potentials was markedly delayed bilaterally. Brain MRI scans at

11 months of age showed a 7-month myelination level (about 70% of the normal level).

His stature at the age of 4 years 11 months is shown in Table 1. His DQ was about 20 (he walked with support, spoke no words and identified eyes, ears and mouth). Rigidospastic diplegia with a mild athetotic movement of the upper limbs was noted.

Patient 2 (III-9)

This child was born at 39 weeks of gestation with a birth weight of 2938 g after an uncomplicated pregnancy to healthy, nonconsanguineous Japanese parents (mother, age 29, father 31). His Apgar score was 9. On day 5, phototherapy was carried out for 24 h. He could control his head at 4 months and rolled over at 6 months of age. MRI scans at 6 months of age showed a 4-month myelination level (about 70% of the normal level). His DQ was about 50 at 11 months of age. Clinical and laboratory findings are summarized in Table 1. His development and athetoid movements were the same as those in Patient 1.

Patient 3 (III-10)

Patient 3 was born at 40 weeks of gestation with a birth weight of 3060 g after an uncomplicated pregnancy (mother, age 31, father 33). His Apgar score was 9. On day 3, serum total bilirubin level increased but phototherapy was not carried out. He was able to control his head at 3 months and rolled over at 8 months of age. He was diagnosed as having cerebral palsy. His height was 74.0 cm (mean), weight 6.97 kg (-2.3 SD) and OFC 44.5 cm (-1.0 SD) at 9 months of age. Brain MRI scans at 9 months of age showed a 6-month myelination level (about 70% of the normal level). He sat at 1 year 5 months of age. DQ was about 50 at 2 years and 1 months of age. Clinical and laboratory findings are summarized in Table 1. His development and athetoid movements were the same as those in Patient 1.

Table 1. Clinical and laboratory findings in three patients

	Patients			
	III-7	III-9	III-10	
Age	4 years 11 months	8 years 11 months	6 years 10 months	
Birth weight (g)	3490	2938	3060	
Phototherapy	+	+	-	
Transient poor weight gain	+	+	+	
Physical findings	Stature (SD)			
	Height/weight/OFC	-0.6/-2.1/-1.1	-0.8/-1.6/-1.0	-0.8/-1.0/-2.0
	Minor anomalies	-	-	-
	Hepatosplenomegaly	-	-	-
	Macroorchidism	-	-	-
	Ocular fundus	N	N	N
Neurological findings	DQ	< 20	< 20	< 20
	Rigidospastic diplegia	+	+	+
	Athetoid movements (mild)	+	+	+
Laboratory findings	Transaminases	N	N	N
	Amino acids (plasma)	N	N	N
	Organic acids (urine)	N	N	N
	VLCFA (serum)	N	N	N
	Lysozymal enzymes (leukocytes)	N	N	N
	Anti-HTLV-I antibody	nt	-	-
	T-cell subsets	N	N	N
	Karyotype (G-banding)	N	N	N
	FRAXA/FRAXE genes	N	N	N
	Proteolipid protein gene	N	nt	nt
	LICAM gene	N	N	N
	Electroencephalogram	N	N	N
	Delayed myelination on MRI	+(11 months)	+(6 months)	+(9 months)

DQ, developmental quotient; FRAXA, fragile X; FRAXE, fragile XE; HTLV-I, human T-cell leukemia virus-I; LICAM, L1 cell adhesion molecule; MRI, magnetic resonance imaging; N, normal; nt, not tested; OFC, occipito-frontal circumference; VLCFA, very long chain fatty acid.

Molecular analyses

We investigated fragile X (FRAXA) and fragile XE (FRAXE) genes of the three patients, the proteolipid protein gene of Patient 1 and L1 cell adhesion molecule (LICAM) genes of all three patients using molecular methodology. After obtaining informed consent, genomic DNAs were isolated from peripheral blood lymphocytes of the patients for study. FRAXA, FRAXE and proteolipid protein genes were analyzed according to the method described in previous research (Nanba et al., 1995; Yamamoto et al., 1998). No abnormal findings were detected.

Genetic analysis of LICAM was performed by DNA sequencing as previously described

(Okamoto et al., 2004; Kanemura et al., 2005). Briefly, amplification of the exons and the exon-intron boundaries of the LICAM gene was performed by PCR using oligonucleotide primers (Jouet et al., 1994). The purified PCR amplification products were directly sequenced using an ABI BigDye Terminator Cycle Sequencing Ready Reaction Kit (Applied Biosystems, Foster City, CA). DNA sequencing was carried out in both directions for each template. No mutation was detected in all exons and exon-intron boundaries in the three patients. The research protocol on LICAM gene analysis was approved by the Medical Research Board of the Ethics Committee of Osaka National Hospital.

Table 2. Differential diagnosis: X-linked mental retardation syndromes with spastic paralysis*

Syndrome	OMIM	Reference	Additional signs and symptoms
PPM-X	300055	Lindsay et al. [1996]	Psychosis, macroorchidism
Spastic paraplegia 16	300266	Steinmuller et al. [1997]	Aphasia, reduced vision, dysfunction of bowel/bladder
Allan-Herndon-Dudley	300523	Stevenson et al. [1990]	Characteristic face, ataxia, athetoid movements
Cantagrel	300524	Cantagrel et al. [2004]	Mild facial dysmorphism, stereotypic movements
JARID1C-related XLMR	300534	Claes et al. [2000]	Facial hypotonia, maxillary hypoplasia
ATR-X syndrome	301040	Martinez et al. [1998]	Short stature, facial dysmorphism, microcephaly
Cerebellar ataxia 2	302500	Apak et al. [1989]	Spinocerebellar ataxia
MASA (L1CAM)	303350	Fransen et al. [1997]	Aphasia, shuffling gait, adducted thumbs
Renpenning syndrome	309470	Sutherland et al. [1988]	Short stature, microcephaly, small testis
Fitzsimmons	309560	Fitzsimmons et al. [1983]	Pes cavus, palmoplantar hyperkeratosis
Smith-Fineman-Myers	309580	Guion-Almeida et al. [1998]	Unusual facial appearance, seizures, deafness
Schimke XLMR	312840	Schimke et al. [1984]	Choreoathetosis, deafness, ophthalmoplegia
Spastic paraplegia 2 (PLP1)	312920	Cailloux et al. [2000]	Dysarthria, nystagmus, optic atrophy
Hooft		Hooft et al. [1968]	Choreo-athetosis, microcephaly, peculiar appearance
Siber		Siber [1984]	Microphthalmia with corneal opacities, hypospadias
Arena		Arena et al. [1992]	Ataxia, titubation, iron deposits in basal ganglia

ATR-X, X-linked alpha-thalassemia/mental retardation; JARID1C, Jumonji AT-rich interactive domain 1C; L1CAM, L1 cell adhesion molecule; OMIM, Online Mendelian Inheritance in Man; PLP, proteolipid protein; XLMR, X-linked mental retardation.

* Pyramidal sign or spasticity is included.

Discussion

Three affected patients in this family were characterized by severe MR, rigidospastic diplegia, mild athetotic movement of upper limbs, delayed myelination on MRI and transient poor weight gain. Neurological findings were nonprogressive. Deterioration of development, convulsion, cerebellar signs (ataxia and nystagmus), dysarthria, pseudobulbar sign, minor anomalies including facial dysmorphism, hepatosplenomegaly, scoliosis and joint contractures were not observed. No abnormal ocular and auditory findings were found. Results of various biochemical analyses and anti-human T-cell leukemia virus-I antibody titers were normal. Repeat expansions were not

detected at FRAXA and FRAXE sites. No mutation was detected in all exons and exon-intron boundaries of L1CAM gene. These findings were almost consistent in all affected patients (Table 1). XL recessive inheritance is most likely since all patients are male, female siblings were unaffected and both mothers and one grandmother are neurologically normal.

For differential diagnosis, a review by Chiurazzi et al. (2004), in which a total of 209 XLMR conditions (135 recessive and eight dominant disorders, and 66 nonspecific XLMR conditions are listed) was searched. Information from the "XLMR Update WebSite" last updated on 1 September 2005 by Pietro Chiurazzi [<http://xlmr.interfree.it/home.htm>] and PubMed [<http://www.ncbi.nlm.nih.gov>] up until November 2005 were

searched as well. From a total of 40 distinct conditions in which XLMR was associated with paralysis (spastic paraplegia, diplegia, quadriplegia or pyramidal tract signs) selected from these three literature sources, 24 conditions were excluded because of progressive course [MR with spastic paraplegia (Davis et al., 1981), XLMR with progressive spasticity (Meloni et al., 2000), etc.], hydrocephalus [Fried syndrome (Strain et al., 1997)], cerebral and cerebellar malformations [Pettigrew/MRXS5 syndrome (Pettigrew et al., 1991, etc.)], myoclonic epilepsy [myoclonic epilepsy with MR (Scheffer et al., 2002), etc.], blindness [(Hamel BCD syndrome (Hamel et al., 1999)], etc. Consequently, 16 entities are listed in Table 2.

One of the characteristic findings in our patients is delayed myelination on MRI. With the development of MRI diagnostics, this finding would be expected more frequently. We analyzed the PLP gene implicated in myelination by means of single strand conformation polymorphism (SSCP), which proved normal. No mutation was detected in all exons and exon-intron boundaries of the L1CAM gene as well. Our cases had mild athetotic movements in the upper limbs besides MR and diplegia. Choreoathetosis has been described in several XLMR syndromes associated with spasticity. Baar and Gabriel (1966) and Bundy and Griffiths (1977) [OMIM 312890], both of which were incorporated into spastic paraplegia 2 [OMIM 312920], reported this as related to athetotic movements, ataxia and nystagmus. Hoof et al. (1968) and Schimke et al. (1984) also reported families with choreoathetosis which are unequivocally different from our cases. Bialer et al. (1992) reported a family in which nine men in three generations presented spastic quadriparesis and varying degrees of psychomotor retardation. Although they had some similarities to the present patients, characteristic facial expression, muscle hypoplasia, progressive paresis and pseudobulbar signs were not recognized in our patients. To our knowledge, there are no reports of the same

condition in the literature despite our extensive search. We conclude that our cases represent a new XLMR syndrome with rigidospastic diplegia based on the above sources.

References

- 1 Apak S, Yuksel M, Ozmen M, Saka N, Darendeliler F, Neuhauser G. Heterogeneity of X-linked recessive (spino) cerebellar ataxia with or without spastic diplegia. *Am J Med Genet* 1989;34:155–158.
- 2 Arena JF, Schwartz C, Stevenson R, Lawrence L, Carpenter A, Duara R, et al. Spastic paraplegia with iron deposits in the basal ganglia: a new X-linked mental retardation syndrome. *Am J Med Genet* 1992;43:479–490.
- 3 Baar HS, Gabriel AM. Sex-linked spastic paraplegia. *Am J Ment Defic* 1966;71:13–18.
- 4 Bialer MG, Lawrence L, Stevenson RE, Silverberg G, Williams MK, Arena JF, et al. Allan-Herndon-Dudley syndrome: clinical and linkage studies on a second family. *Am J Med Genet* 1992;43:491–497.
- 5 Bunday S, Griffiths MI. Recurrence risks in families of children with symmetrical spasticity. *Dev Med Child Neurol* 1977;19:179–191.
- 6 Cabezas DA, Arena JF, Stevenson RE, Schwartz C, Goldberg S, Morales A, et al. XLMR database. *Am J Med Genet* 1999;85:202–205.
- 7 Cailloux F, Gauthier-Barichard F, Mimault C, Isabelle V, Courtois V, Giraud G, et al. Clinical European Network on Brain Dysmyelinating Disease. Genotype-phenotype correlation in inherited brain myelination defects due to proteolipid protein gene mutations. *Eur J Hum Genet* 2000;8:837–845.
- 8 Cantagrel V, Lossi A-M, Boulanger S, Depetris D, Mattei M-G, Gecz J, et al. Disruption of a new X linked gene highly expressed in brain in a family with two mentally retarded males. *J Med Genet* 2004;41:736–742.
- 9 Chiurazzi P, Tabolacci E, Neri G. X-linked mental retardation (XLMR): from clinical conditions to cloned genes. *Clin Rev Clin Lab Sci* 2004;41:117–158.
- 10 Claes S, Devriendt K, Van Goethem G, Roelen L, Meireleire J, Raeymaekers P, et al. Novel syndromic form of X-linked complicated spastic paraplegia. *Am J Med Genet* 2000;94:1–4.
- 11 Davis JG, Silverber G, Williams MK, Spiro A, Shapiro LR. A new X-linked recessive mental retardation syndrome with progressive spastic quadriparesis. *Am J Hum Genet* 1981;33:75A.
- 12 Fitzsimmons JS, Fitzsimmons EM, McLachlan JJ, Gilbert GB. Four brothers with mental retardation, spastic paraplegia and palmoplantar hyperkeratosis. A new syndrome? *Clin Genet* 1983;23:329–335.

- 13 Fransen E, Van Camp G, Vits L, Willems PJ. L1-associated diseases: clinical geneticists divide, molecular geneticists unite. *Hum Mol Genet* 1997;6:1625–1632.
- 14 Guion-Almeida ML, Tabith A Jr, Kokitsu-Nakata NM, Zechi RM. Smith-Fineman-Myers syndrome in apparently monozygotic twins. *Am J Med Genet* 1998;79:205–208.
- 15 Hamel BC, Wesseling P, Renier WO, van den Helm B, Ropers HH, Kremer H, et al. A new X linked neurodegenerative syndrome with mental retardation, blindness, convulsions, spasticity, mild hypomyelination and early death maps to the pericentromeric region. *J Med Genet* 1999;36:140–143.
- 16 Hamel BCJ, Chiurazzi P, Lubs HA. Syndromic XLMR genes (MRXS): update 2000. *Am J Med Genet* 2000;94:361–363.
- 17 Hooft C, de Hauwere R, van Acker KJ. Familial non-congenital microcephaly, peculiar appearance, mental and motor retardation, progressive evolution to spasticity and choreo-athetosis. *Helv Paediatr Act* 1968;23:1–12.
- 18 Jouet M, Rosenthal A, Armstrong G, MacFarlane J, Stevenson R, Paterson J, et al. X-linked spastic paraplegia (SPG1), MASA syndrome and X-linked hydrocephalus result from mutations in the L1 gene. *Nature Genet* 1994;7:402–407.
- 19 Kanemura Y, Takuma Y, Kamiguchi H, Yamasaki M. First case of LICAM gene mutation identified in MASA syndrome in Asia. *Congenit Anom* 2005;45:67–69.
- 20 Lindsay S, Splitt M, Edney S, Berney TP, Knight SJL, Davies KE, et al. PPM-X: a new X-linked mental retardation syndrome with psychosis, pyramidal signs, and macroorchidism maps to Xq28. *Am J Hum Genet* 1996;58:1120–1126.
- 21 Lubs HA, Chiurazzi P, Arena J, Schwartz C, Tranebjaerg L, Neri G. XLMR genes: update 1998. *Am J Med Genet* 1999;83:237–247.
- 22 Martinez F, Tomas M, Millan JM, Fernandez A, Palau F, Prieto F. Genetic localisation of mental retardation with spastic diplegia to the pericentromeric region of the X chromosome: X inactivation in female carriers. *J Med Genet* 1998;35:284–287.
- 23 Meloni I, Bruttini M, Longo I, Mari F, Rizzolio F, D'Adamo P, et al. A mutation in the Rett syndrome gene, MECP2, causes X-linked mental retardation and progressive spasticity in males. *Am J Hum Genet* 2000;67:982–985.
- 24 Nanba E, Kohno Y, Matsuda A, Yano M, Sato C, Hashimoto K, et al. Non-radioactive DNA diagnosis for the fragile X syndrome in Japanese mentally retarded males. *Brain Dev* 1995;17:317–321.
- 25 Okamoto N, Del Maestro R, Valero R, Monros E, Poo P, Kanemura Y, et al. Hydrocephalus and Hirschsprung's disease with a mutation of LICAM. *J Hum Genet* 2004;49:334–337.
- 26 Pettigrew AL, Jackson LG, Ledbetter DH. New X-linked mental retardation disorder with Dandy-Walker malformation, basal ganglia disease, and seizures. *Am J Med Genet* 1991;38:200–207.
- 27 Roeleveld N, Zielhuis GA, Gabreels F. The prevalence of mental retardation: a critical review of recent literature. *Dev Med Child Neurol* 1997;39:125–132.
- 28 Scheffer IE, Wallace RH, Phillips FL, Hewson P, Reardon K, Parasivam G, et al. X-linked myoclonic epilepsy with spasticity and intellectual disability. Mutation in the homeobox gene ARX. *Neurology* 2002;59:348–356.
- 29 Schimke RN, Horton WA, Collins DL, Therou L. A new X-linked syndrome comprising progressive basal ganglion dysfunction, mental and growth retardation, external ophthalmoplegia, postnatal microcephaly and deafness. *Am J Med Genet* 1984;17:323–332.
- 30 Siber M. X-linked recessive microencephaly, microphthalmia with corneal opacities, spastic quadriplegia, hypospadias and cryptorchidism. *Clin Genet* 1984;26:453–456.
- 31 Steinmuller R, Lantigua-Cruz A, Garcia-Garcia R, Kostrzewa M, Steinberger D, Muller U. Evidence of a third locus in X-linked recessive spastic paraplegia. *Hum Genet* 1997;100:287–289.
- 32 Stevenson RE, Goodman HO, Schwartz CE, Simensen RJ, McLean WT, Herndon CN. Allan-Herndon syndrome. I. Clinical studies. *Am J Hum Genet* 1990;47:446–453.
- 33 Strain L, Wright AF, Bonthron DT. Fried syndrome is a distinct X linked mental retardation syndrome mapping to Xp22. *J Med Genet* 1997;34:535–540.
- 34 Sutherland GR, Gedeon AK, Haan EA, Woodroffe P, Mulley JC. Linkage studies with the gene for an X-linked syndrome of mental retardation, microcephaly and spastic diplegia (MRX2). *Am J Med Genet* 1988;30:493–508.
- 35 Turner G, Opitz JM. Editorial comment: X-linked mental retardation. *Am J Med Genet* 1980;7:407–415.
- 36 Yamamoto T, Nanba E, Zhang H, Sasaki M, Komaki H, Takeshita K. Jimpysd mouse mutation and connatal Pelizaeus-Merzbacher disease. *Am J Med Genet* 1998;75:439–440.

Received June 6, 2006; accepted July 5, 2006

Corresponding author: Kousaku Ohno, MD