

# A Case of Catamenial Pneumothorax Treated by Video-Assisted Thoracoscopic Surgery

**Sakiko Yasui, Yuji Taniguchi, Yoshimasa Suzuki, Kazuhiko Makihara, Koichiro Okada, Norimasa Ito, Kiyosuke Ishiguro and Shigetsugu Ohgi**

*Division of Organ Regeneration Surgery, Department of Surgery, School of Medicine, Tottori University Faculty of Medicine, Yonago 683-8504 Japan*

**This is a case of a 47-year-old female who had a medical history of right pneumothorax for the second time. The pneumothorax, accompanying the start of menstruation, recurred and the patient was hospitalized. From the medical history, a catamenial pneumothorax was suspected. As for intraoperative findings, many small fenestrations of 1 mm or 3 mm were present in the border region with the muscle bundle of the central tendon of the diaphragm. The lesion site of the diaphragm and the apex area as a biopsy were partially excised under video-assisted thoracoscopic surgery. Although a postoperative Gn-RH agonist was started for endometriosis, it was stopped because side effects appeared. Because the right pneumothorax recurred in accordance with the start of menstruation, the treatment was changed to danazol. To date, the pneumothorax has not recurred.**

**Key words:** catamenial pneumothorax; diaphragmatic fenestration; hormonal therapy; video-assisted thoracoscopic surgery

Catamenial pneumothorax is a disease in which a pneumothorax repeats in accordance with the menstruation cycle (Maurer et al., 1958). While there are many unknown points regarding the mechanism of its occurrence, however, this disease is assumed to be caused by endometriosis. Thus, because endometriosis cases have increased recently, this disease is expected to increase in the future as well. We experienced a case of a patient in whom a perforated site of the diaphragm was excised under video-assisted thoracoscopic surgery (VATS) and the disease recurred when hormonal therapy was stopped after surgery. The case is reported here with a discussion of the literature.

## Patient Report

In 1998, a 45-year-old female consulted a local physician because right chest pain and dyspnea appeared suddenly. The symptoms were alleviated by conservative treatment, specifically an analgetic. In the middle of December 2000, right chest pain and dyspnea recurred and the patient again consulted the physician. The symptoms were not alleviated by the same treatment. On December 27, she was referred to the Clinic of Respiratory Internal Medicine of Tottori University Hospital and admitted as a patient. Diagnosis as right spontaneous pneumothorax was made and the symptoms were alleviated by continuous chest drainage. Because the pain occurred at the start of her menstruation, catamenial pneumothorax was suspected. The patient was followed-up at the outpatient section after discharge.

---

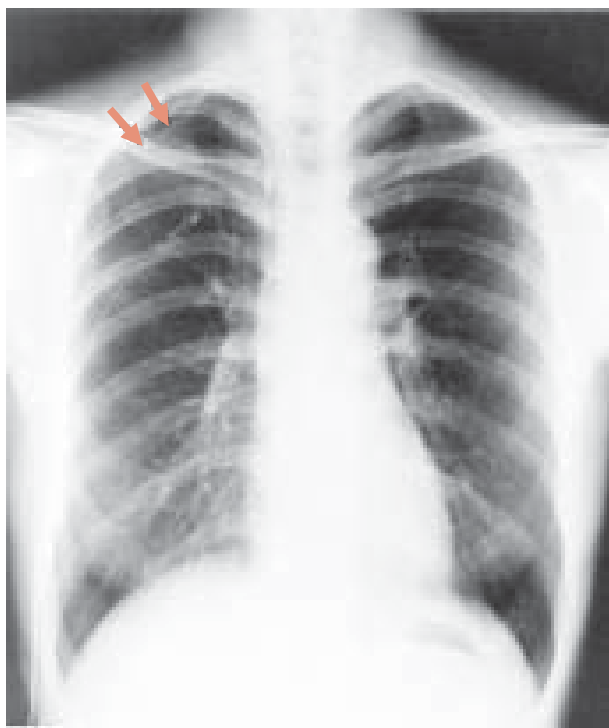Abbreviation: VATS, video-assisted thoracoscopic surgery

On February 18, 2001, pain recurred 2 days prior to her menstruation. On February 21, she consulted the Clinic again. Because a recurrence of the right pneumothorax was found, she was immediately hospitalized in the Clinic of Thoracic Surgery, Tottori University Hospital.

The patient had experienced 2 pregnancies but only 1 delivery. Her menstruation was regular, but with dysmenorrhea. There was no past illness that was especially notable.

On admission, her height was 155 cm, body weight 45 kg, and nutrition was slightly poor. Body temperature was 36.6°C, blood pressure 100/72 mmHg and pulse rate 70/min. Auscultation revealed faint respiratory sounds in the right lung. There were no rale sounds or cardiac murmur. There were no abnormal physical findings in the abdomen.

Chest X-rays showed a right pneumothorax without bulla or pleural effusion. Although continuous chest drainage was conducted, complete pulmonary expansion was not obtained (Fig. 1). Computed tomography of the chest showed no bulla or




**Fig. 1.** Preoperative Chest roentgenogram showing a right pneumothorax after continuous chest drainage. The arrows indicate visceral pleura.

other abnormal findings. Electrocardiograms also showed no abnormalities. The bleeding time and coagulation time were normal, and no abnormalities were found in hematological examinations, urinalysis, biochemical examinations, etc.

On February 28, 2001, VATS was performed in a recumbent position on the inferior left side under general anesthesia with separate ventilation. A thoracoport of 5.5 mm was inserted through the 5th intercostal middle axillary line and the inside of the thorax was observed with a hard scope. Irregular hypertrophic pleura were found at the apex area in the right thorax, but no bulla or adhesions were present. Subsequently, a thoracoport of 11.5 mm was inserted through the 4th intercostal anterior axillary line, and another one of 5.5 mm through the 6th intercostal scapular angle for further observation. A small fenestration of about 3 mm in diameter was found in the tendon center of the diaphragm and air bubbles were present around it. Deposits of a blackish brown color and small pores of about 1 mm in diameter were also observed around the diaphragm. From these findings, the disease was diagnosed as catamenial pneumothorax. The tendon center of the diaphragm, including the small pores, was resected using an ENDO GIA Universal 30-2.5 (United States Surgical Corp., Norwalk, CT). The hypertrophic pleura in the apex part were also resected, using an ENDO GIA Universal 45-2.5 (United States Surgical Corp.).

The sizes of the excised sections were 33 × 11 mm from the diaphragm (Fig. 2) and 33 × 5 mm from the apex. In the diaphragm, there was a slit-like partial change of 7 mm, and mild chronic inflammation was found around it, which is not generally observable in disease as endometriosis. In the apex section, a severe pneumonic change and a non-specific fibrous formation were found just under the pleura, but no tissue indicating endometriosis or pneumothorax.

Although a postoperative atelectasis occurred in the right pulmonary inferior lobe, it improved on day 5. Subsequently, its course was favorable. During gynecological examination, endometriosis of the intraperitoneal organs was not detected. However, since the serum CA125 level increased to



**Fig. 2.** The excised diaphragm showing the perforation penetrating the intraperitoneum. The scale indicates 1 cm.

76.3 and laparoscopy examination was not performed, the possibility of endometriosis was undeniable. The patient was discharged 15 days after surgery, and administration of leuprorelin acetate, an Gn-RH agonist, was started. Because symptoms of carpal tunnel syndrome appeared, which might have been caused by the growth of smooth muscle, its administration was stopped 4 months later. After 4 months, following the cessation of hormonal therapy, on November 10, 2001, 1 day prior to the start of her menstruation, the pneumothorax with right chest pain recurred. However, the collapse was so mild that the symptoms cured naturally. On November 16, oral administration of danazol was started. At present, the pneumothorax has not recurred after 1 year.

### Discussion

Although there is no consistent view regarding a mechanism for the occurrence of catamenial pneumothorax, there are 3 hypotheses: the intraperitoneal air theory (Maurer et al., 1958), the subpleu-

ral endometrial implant theory (Lillington et al., 1972) and the prostaglandin F<sub>2</sub> $\alpha$  theory (Rossi and Goplerud, 1974). As for the intraperitoneal air theory, it is assumed that air entering the abdominal cavity through the uterine and fallopian tubes at the time of menstruation could enter the thorax through a defective pore due to diaphragmatic endometriosis, and thus cause a pneumothorax (Maurer et al., 1958). In our patient, because small fenestrations were found in the right diaphragm and pneumothorax was not found in the lung, this hypothesis is considered highly likely. Histologically, although no endometrial tissue was found in the diaphragm, the tissue might have fallen out, causing formation of the small pore (Shiraishi, 1991).

This disease was diagnosed as catamenial pneumothorax before surgery, because it was right pneumothorax in a middle-aged female and the symptoms repeated around the start of her menstruation. Presence of the diaphragmatic fenestrations, as an intraoperative finding, and her having a normal lung, created a relatively certain diagnostic basis. After surgery, hormonal therapy was started and pneumothorax did not recur during that period.

Four months after the treatment was stopped, right pneumothorax recurred in accordance with the start of her menstruation. From the positive effects of the hormonal therapy, it was again highly possible that this case was a catamenial pneumothorax.

Treatments for this patient focused on surgical and hormonal therapies. Indication for therapy depended on the severity and frequency of the pneumothorax, age and patient's desire for pregnancy. Surgical therapy included closure of the diaphragmatic fenestration and pleural symphysis, with the frequent use of VATS. However, the recurrence rate of cases in which diaphragmatic lesions were excised is high, 21% (Banba et al., 1983). In our patient, because a large number of preliminary lesions were observed in the diaphragm during surgery, the recurrence after surgery may have been due to a new fistula occurring at another site on the diaphragm. However, this surgery is used normally when the pneumothorax is causing the problem, yet may simultaneously be a very useful method for creating a diagnostic standard for discounting natural pneumothorax due to bulla, observation of diaphragmatic defective pores and allopatric endometriosis in the pleura (Inagaki et al., 1999).

Hormonal therapy follows drug treatment for endometriosis, including testosterone derivatives, Gn-RH agonists and oral contraceptives (Slabbynck et al., 1991). However, it is difficult to continue this therapy because of the appearance of side effects (Banba et al., 1983), and because when it is stopped, the symptoms recur; thus this therapy has not been established as a complete treatment method. To es-

tablish a more effective treatment method, it will be necessary to elucidate endometriosis as a prognostic background as well as other related pathologic conditions.

## References

- 1 Bamba J, Masaki M, Kohda S, Matsushita H. Treatment of catamenial pneumothorax. *Nippon Kyobu Shikkan Gakkai Zasshi* 1983;42:571–577 (in Japanese with English abstract).
- 2 Inagaki M, Usui S, Okazaki H, Funakoshi N. A case of catamenial pneumothorax resected of diaphragmatic endometriosis thoroscopically. *Nippon Kokyuku Gakkai Zasshi* 1999;13:779–783 (in Japanese with English abstract).
- 3 Lillington GA, Mitchell SP, Wood GA. Catamenial pneumothorax. *JAMA* 1972;219:1328–1332.
- 4 Maurer ER, Schaal JA, Mendez FL. Chronic recurrent spontaneous pneumothorax due to endometriosis of the diaphragm. *JAMA* 1958;168:2013–2014.
- 5 Rossi NP, Goplerud CP. Recurrent catamenial pneumothorax. *Arch Surg* 1974;109:173–176.
- 6 Shiraishi T. Catamenial pneumothorax: report of a case and review of the Japanese and non-Japanese literature. *Thorac Cardiovasc Surg* 1991;39:304–307.
- 7 Slabbynck H, Laureys M, Impens N, De Vroey P, Schandevyl W. Recurring catamenial pneumothorax treated with a Gn-RH analogue. *Chest* 1991;100:851.

*Received December 9, 2002; accepted December 18, 2002*

*Corresponding author: Sakiko Yasui*