

Antemortem Diagnosis of Cardiac Metastasis Available in a Patient with Primary Tongue Carcinoma

Katsuyuki Kawamoto, Aya Nosaka and Hiromi Takeuchi

Department of Oto-Rhino-Laryngology, Tottori University Faculty of Medicine, Yonago 683-0826 Japan

We report a rare case of a patient suffering from cardiac metastasis with tongue carcinoma. A 71-year-old Japanese man was admitted to our clinic at Tottori University Hospital in June 1997. We diagnosed his disease as stage T2 N2 M0 squamous cell carcinoma of the tongue, and performed a partial resection of the tongue and a right-side radical neck dissection. The postoperative course was uneventful, and follow-up was continued. In March 1998, he visited us complaining of anorexia and constipation. On electrocardiogram (ECG), ST waves were elevated in leads I, aVL, V5 and V6, and depressed in lead aVF. Cardiac echogram revealed a shadow-like tumor in the lower portion at the lateral wall of the left ventricle. He had a sudden and serious arrhythmic attack on 12 March, and he died of cardiac insufficiency by arrhythmia on 22 March 1998. An autopsy showed that a cardiac tumor had invaded mainly into the anterior and lateral wall of the left ventricle, and had reached the septum. Microscopically, the tongue carcinoma had invaded the myocardium. With the uncommon ECG and cardiac-echographic findings, we could clinically make an antemortem diagnosis for the present patient. The paucity of antemortem diagnosis of cardiac metastasis in the literature emphasizes the uniqueness.

Key words: cardiac echography; cardiac metastasis; tongue carcinoma

Cardiac metastasis with tongue carcinoma is comparatively rare. Most reports on cardiac metastases have presented cases of invasion into the right atrium or ventricle, and metastasis to the left ventricle is quite uncommon. It is difficult to find a metastatic cardiac tumor in antemortem examinations because there are no characteristic findings in clinic or on electrocardiogram (ECG). The disease has been discovered at autopsy in most cases. When an antemortem diagnosis of cardiac metastasis of a malignant tumor is made, it is often difficult to apply a curative therapy because most cardiac metastases are spread by a systematic route, causing a critical status in general. But, if the cardiac metastasis is discovered early by ECG or cardiac echogram, apothanasia with chemotherapy or radiation therapy would be possible. There-

fore, antemortem diagnosis of cardiac metastasis is significant. We report a rare case of a patient with tongue carcinoma with cardiac metastasis in the left ventricle, in which antemortem diagnosis was available by ECG and echocardiography.

Patient Report

In June 1997, a 71-year-old Japanese man was admitted to our hospital with a swallowing disturbance due to an oral pain which had lasted for 2 months. In the right margin of the tongue, a tumor 25 mm in diameter was found, which we highly suspected to be tongue carcinoma. Two elastic hard masses 15 mm in diameter were identified by palpation in the right side of the

Table 1. Laboratory findings upon second admission

Laboratory findings	Measured values	Normal values
White blood cell count ($\times 10^3/\text{mm}^3$)	18.6	3.3 – 8.8
Red blood cell count ($\times 10^6/\text{mm}^3$)	3.20	4.00 – 5.70
Hemoglobin (g/dL)	10.6	12.0 – 17.0
Platelet count ($\times 10^3/\text{mm}^3$)	476	125 – 343
Total protein (g/dL)	7.1	6.0 – 8.0
Albumin (g/dL)	3.1	3.5 – 5.0
Total bilirubin (mg/dL)	1.0	0.2 – 1.2
Serum creatinine (mg/dL)	0.9	0.7 – 1.7
Serum sodium (mEq/L)	140	137 – 147
Serum potassium (mEq/L)	3.2	3.6 – 5.0
Serum calcium (mEq/L)	11.8	8.6 – 11.0
C-reacting protein (mEq/L, milliequivalent/liter)	15.21	< 0.2

neck. Pathology of the biopsy specimen of the tongue tumor revealed a low or moderately differentiated squamous cell carcinoma. By echography and computed tomography (CT), the 2 neck masses were suspected of being metastatic from the tongue carcinoma. Distant metastases into the chest, abdomen, pelvic cavity and limbs were not identified by CT and gadolinium scintigraphy. Diagnosed as stage T2 N2 M0 tongue

carcinoma, radiation therapy was applied by irradiating a 30-Gy dose, and then a partial resection of the tongue and a right-side radical neck dissection were performed in August 1997. Histological examination of the right margin of the tongue showed no cancer cells. The post-operative course was uneventful, and follow-up was carried out through periodical ambulatory examinations.

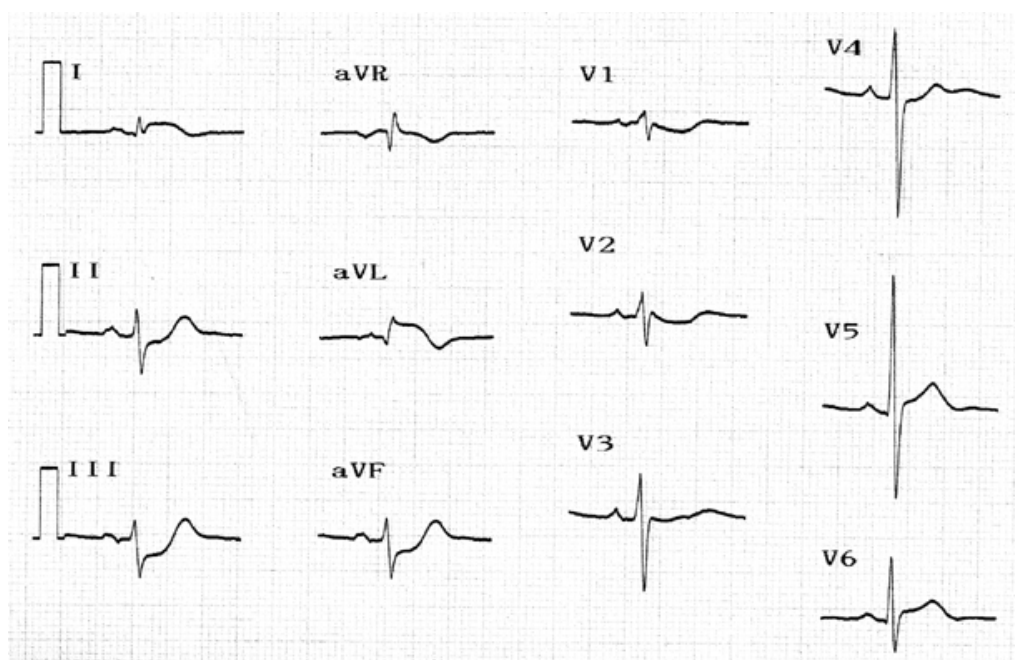


Fig.1. ECGs showing ST elevations in leads I, aVL, V5 and V6, and a ST depression in lead aVF.

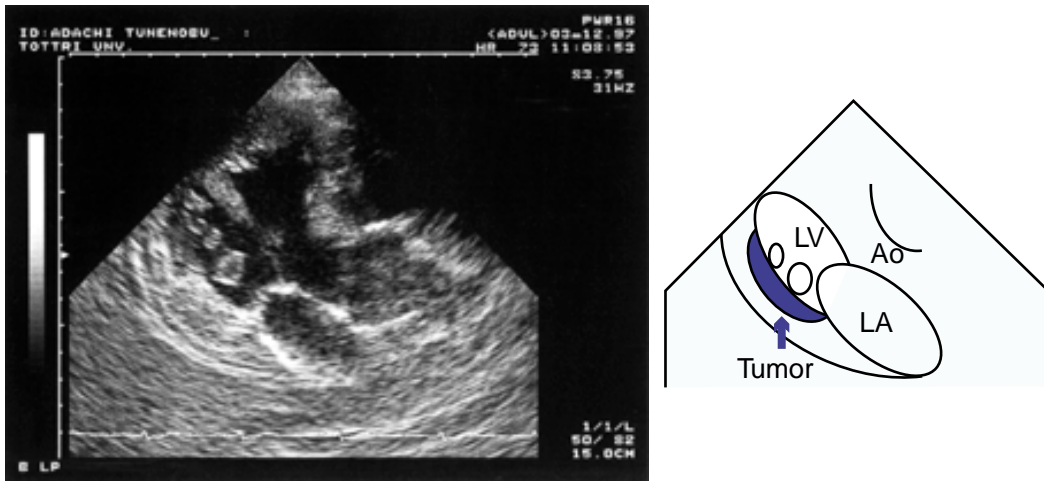


Fig. 2. A cardiac echogram with its schema showing a tumor mass in the left ventricle. LV, left ventricle; LA, left atrium; Ao, aorta.

Since February 1998, however, anorexia and constipation appeared. Because the symptoms did not improve, he was admitted again in March 1998. On admission, there was no sign of recurrence in the tongue, mesopharynx, hypopharynx, esophagus or neck. His blood pressure was 103/60 mmHg, and his pulse rate was 78 beats/min. Laboratory findings revealed hyperleucocytosis, hyponatremia, hypercalcemia

and a high value of C-reacting protein (Table 1). ECGs showed elevations of ST waves in leads I, aVL, V5 and V6, and a depression in lead aVF (Fig. 1). Cardiac echography revealed a tumor mass in the lower portion of the lateral wall of the left ventricle (Fig. 2). Sudden and serious arrhythmias were provoked on 12 March 1998, and he died on 22 March of cardiac insufficiency by arrhythmia. The post-

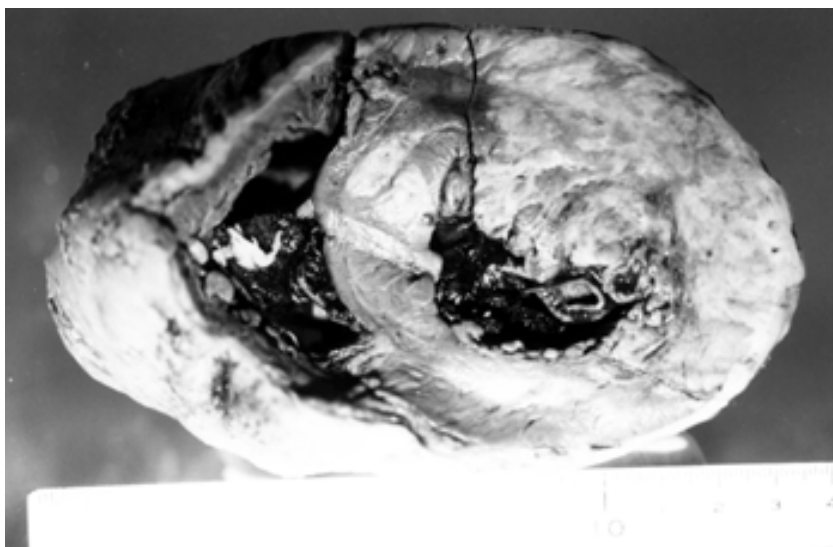


Fig. 3. The heart at autopsy. The metastatic tumor mainly exists in the anterior and lateral wall of the left ventricle, reaching to the septum.

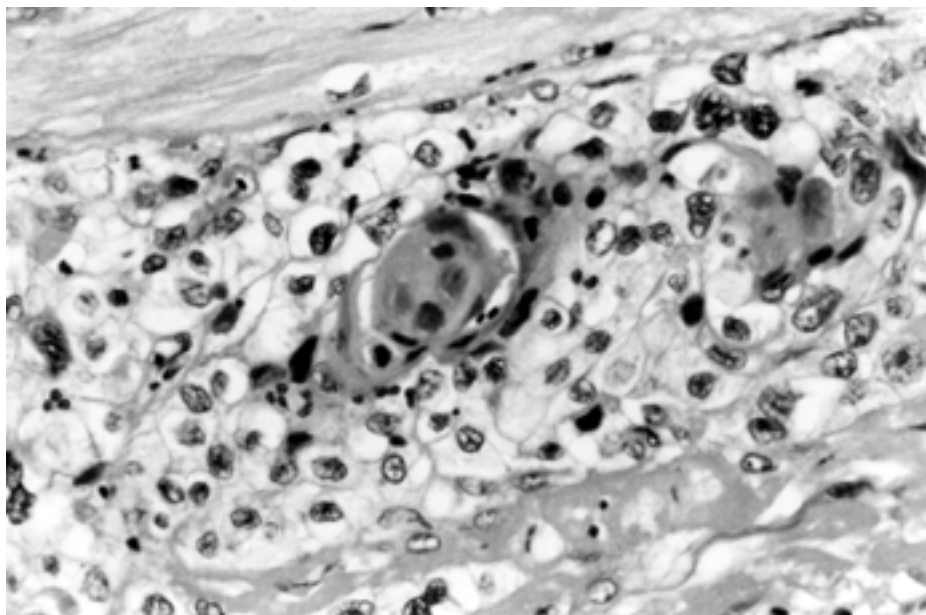


Fig. 4. Tumor cells composed of squamous cell carcinoma. Hematoxylin eosin stain, $\times 200$.

mortem examination showed the heart was 550 g in weight and involved in the tumor. The cardiac tumor metastasized mainly into the anterior and lateral wall of the left ventricle, and reached the septum (Fig. 3). Microscopically, a low or moderately differentiated type of squamous cell carcinoma invaded the myocardium (Fig. 4). Other distant metastases were found at autopsy in the right lung, bilateral adrenal glands, renal chorion, bilateral kidneys and right upper extremity.

Discussion

Concerning the incidence of cardiac metastases from malignant tumors, Abraham et al. (1990) reported 11.8% and Nakayama et al. (1966), 9.7%. However, reported incidences have varied according to the type of institutions, because cardiac metastases are generally found at autopsy, and clinically evident cardiac metastases are uncommon (Abraham et al., 1990). Malignant tumors of the head and neck with cardiac metastases are particularly rare. Among tumors of

the head and neck, primary malignant tumors of the tongue are frequent (DeLoach and Haynes, 1953; Nakayama et al., 1966). Nakayama et al. (1966) reported that cardiac metastases were found at autopsy in 6 of 12 patients with tongue carcinomas. Myocardial or pericardial involvement was observed at autopsy in 1 of 9 patients with tongue carcinomas (DeLoach and Haynes, 1953), and in 2 of 126 patients with primary tongue carcinoma (Gasman et al., 1955). To the best of our knowledge, antemortem diagnosis was reported only in 3 cases, including the present one, of squamous cell carcinoma of the tongue with metastasis to the heart (Werbel et al., 1985; Rivkin et al., 1999). Concerning the distribution of metastases within the heart, Abraham et al. (1990) carried out postmortem examinations for 3314 cases over a 14-year period, and reported that the myocardium was the most common site (53.9%), followed by the pericardium (28.4%), epicardium (13.7%) and endocardium (3.9%). Most reported cases of cardiac metastases have been involved in the right atrium or ventricle, and metastases in the left ventricle have been quite uncommon. The

present case suffered from a metastatic tumor in the left ventricle, presumably spread by the hematogenous route.

Cardiac metastases have no characteristic symptoms nor peculiar ECG findings. Differentiation of cardiac metastases from ischemic heart disease or endocarditis is difficult. Bisel et al. (1953) reported a retrospective survey on ECG findings in 59 patients with cardiac metastasis: ECGs showed normal findings in 42% and abnormal findings in 58%. Of the abnormal findings, T-wave abnormalities were the most common (14 cases), followed by low-voltage QRS complexes (7 cases), ST-segment deviations (5 cases), Q-wave abnormalities (2 cases) and prolonged A-V conduction (1 case). But these abnormal findings occur also in other diseases such as ischemic heart disease and endocarditis. In our case, follow-up was carried out through periodical ambulatory examination, in which the oral cavity, chest and abdomen were carefully checked by CT. Examination of the heart was not done because there were no suspected symptoms of cardiac metastasis. But with the uncommon ECG and cardiac-echographic findings, we could clinically have made an antemortem diagnosis in retrospect. Because echogram-guided biopsy was not carried out, definite diagnosis depended on postmortem examinations.

Cardiac metastases are highly likely to provoke conduction disorder of the heart, myocardial ischemia and cardiac tamponade. In preventing sudden death, it is important to make a correct diagnosis. However, even if cardiac metastasis is diagnosed, applying curative therapy is difficult because most cardiac metastases are spread by a systematic route, causing a relatively critical status in general. Werbel et al. (1985), Moser et al. (1991) and Murase et al. (1992) reported on resection of cardiac metastasis, but surgery in each case was unsuccessful. Shelburne and Aronson (1940) reported on a conservative treatment for cardiac metastasis, which was irradiation for a case of pericardial effusion. Rivkin et al. (1999) reported treatment by chemotherapy for palliation. In a case of squamous cell carcinoma in the uterine cer-

vix reported by Batchelor et al. (1997), chemotherapeutic treatment applied for 1 year successfully produced no recurrence. For the present patient, application of curative or palliative therapy such as radiation and chemotherapy was not possible because he had already been in a critical status. Almost all patients are considered fatal when they are diagnosed with cardiac metastasis. But, if cardiac metastases of malignant tumors are found early by ECG or cardiac echogram, chemotherapy or radiation therapy could bring apothanasia to patients. The paucity of antemortem diagnosis of cardiac metastasis emphasizes the importance and significance of this.

References

- 1 Abraham KP, Reddy V, Gattuso P. Neoplasms metastatic to the heart: review of 3314 consecutive autopsies. *Am J Cardiovasc Pathol* 1990;3: 195-198.
- 2 Batchelor WB, Butany J, Liu P, Silver MD. Cardiac metastasis from primary cervical squamous cell carcinoma: three case reports and a review of the literature. *Can J Cardiol* 1997;13:767-770.
- 3 Bisel HF, Wroblewski F, LaDue JS. Incidence and clinical manifestations of cardiac metastases. *JAMA* 1953;153:712-715.
- 4 DeLoach JF, Haynes JW. Secondary tumors of the heart and pericardium: review of the subject and report of one hundred thirty-seven cases. *Arch Intern Med* 1953;91:224-249.
- 5 Gassman HS, Meadows R, Baker LA. Metastatic tumors of the heart. *Am J Med* 1955;19:357-356.
- 6 Moser C, Risse N, Langer HJ. Metastasis to the heart as a cause of treatment resistant heart failure. *Dtsch Med Wochenschr* 1991;116:1670-1674.
- 7 Murase H, Akamizu T, Kubota A, Kusaka S. Anaplastic thyroid carcinoma with prominent cardiac metastasis, accompanied by a marked leukocytosis with a neutrophilia and high GM-CSF level in serum. *Int Med* 1992;31:1107-1111.
- 8 Nakayama R, Yoneyama T, Takatani O, Kimura K. A study of metastatic tumors to the heart, pericardium and great vessels. *Jpn Heart J* 1966;7: 227-234.
- 9 Rivkin A, Meara JG, Li K, Potter C, Wenokur R. Squamous cell metastasis from the tongue to the myocardium presenting as pericardial effusion. *Otolaryngol Head Neck Surg* 1999;120:593-595.

10 Shelburne SA, Aronson HS. Tumors of the heart: report of a secondary tumor of the heart involving pericardium and bundle of His with remission following deep roentgen-ray therapy. *Ann Intern Med* 1940;14:728.

11 Werbel GB, Skom JH, Mehlman D, Michaelis LL. Metastatic squamous cell carcinoma to the

heart: unusual case of angina ducubitus and cardiac murmur. *Chest* 1985;88:468–469.

Received May 7, 2001; accepted June 11, 2001

Corresponding author: Dr. Katsuyuki Kawamoto