

A Case of Hepatocellular Carcinoma Metastasizing to the Palatine Tonsil

Kei Nakahara, Satoshi Matsuo, Hiromi Takeuchi and Hisaaki Ikoma

Department of Oto-Rhino-Laryngology, Faculty of Medicine, Tottori University, Yonago 683-0826, Japan

This report presents a very rare case of a patient with a metastasis in the left palatine tonsil from hepatocellular carcinoma (HCC). A 69-year-old man suffered from a mass of about 20 mm in the left palatine tonsil. The biopsy revealed that the mass in the palatine tonsil was a metastatic lesion from HCC. The patient underwent a left palatine tonsillectomy, and metastasis from HCC has not recurred since the operation. With the presentation of this case, we have looked through the literature reported so far.

Key words: tonsillar metastasis; hepatocellular carcinoma; first manifestation

Metastases from hepatocellular carcinoma (HCC) to the oral cavity are rare. We have recently experienced the case of a patient with tonsillar metastases from HCC, which was the first manifestation of the disease. The present article describes the case, with a thorough review of the literature.

Patient Report

A 69-year-old man with a mass of about 20 mm in the left palatine tonsil visited the Department of Oto-Rhino-Laryngology Clinic, Tottori University Hospital in March, 1999. The patient had noticed this mass for about 8 months. During this period, the patient removed it by himself with no complication, but it recurred immediately. The mass existed in the upper portion of the left palatine tonsil (Fig. 1), and its surface was necrotic. Magnetic resonance imaging showed that it was localized in the left palatine tonsil, without invasion to the ambient organs (Fig. 2). Pathological findings were metastases from HCC (Fig. 3). Although he had suffered from alcoholic liver disease with fatty liver for 10 years, there had been no evidence of HCC up to that moment; the tonsillar mass was the first demonstration of the tumor.

Clinical examinations revealed that a tumor

70 × 80 mm in size existed in the right hepatic lobe, which invaded the portal vein. There were no other metastases other than the left palatine tonsil, the alpha-fetoprotein level was positive (1216.0 ng/mL) and hepatic disorders were not severe (Child-A). The disease was non-curable.

The patient underwent a left palatine tonsillectomy under general anesthesia for removing the pharyngeal discomfort and for prevent-

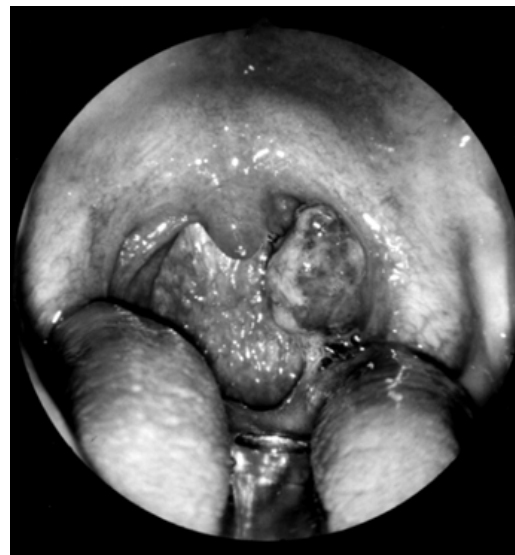

Fig. 1. Oral cavity of the present patient. There is a tumor in the upper portion of the left palatine tonsil.

Abbreviation: HCC, hepatocellular carcinoma

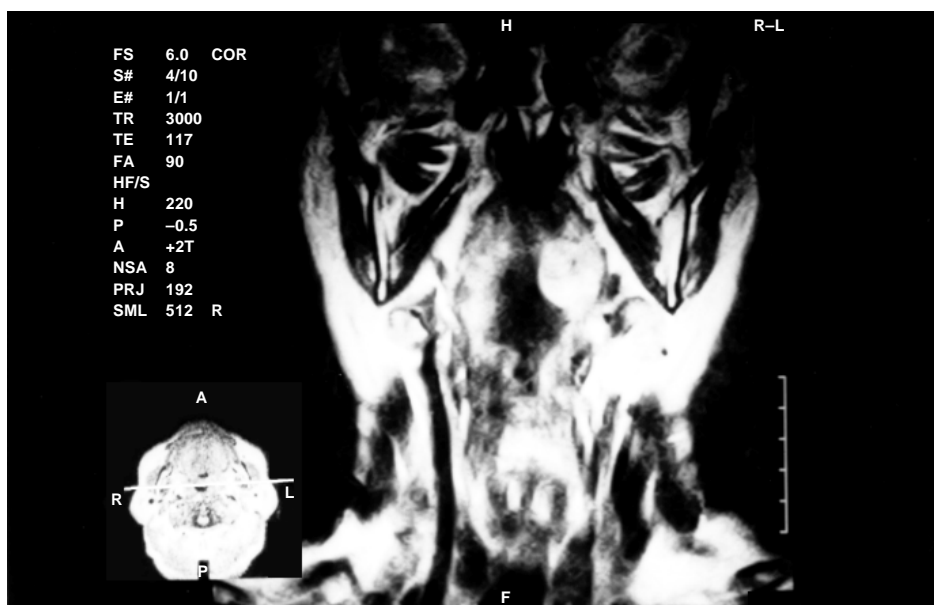


Fig. 2. Magnetic resonance images (T2-weighted coronal views). The tumor is localized in the left palatine tonsil.

ing dyspnea, dysphagia and severe bleeding. The tonsil had no adhesion to the surrounding tissue, and there was no great loss of blood. No evident invasion could be found during the operation. We could not find any evidence of recurrence up to 4 months after the operation.

Discussion

Metastases to the tonsil are uncommon. The known primary tumors are malignant melanoma, carcinomas of the breast, lung and stomach, hypernephromas and seminomas (Brownson et al., 1979). Rarely observed cases are metastases from renal carcinoma, pancreatic carcinoma, Wilms' tumor, choriocarcinoma and mixed mesodermal tumor of the uterus (Fernández Aceñero et al., 1996). Tonsillar metastasis from HCC is quite rare. In Japan, at least 7 Japanese patients were reported from 1981 to 1994. In the West, we could find only 1 patient with HCC metastasizing to the palatine tonsil, reported from San Carlos University Hospital in Spain in 1996 (Llanes et al., 1996).

The primary tumors of tonsillar metastases reported in Japan (Table 1) are: carcinomas of

the lung, stomach, liver, colon, kidney, breast, pancreas, thyroid gland and gallbladder; malignant melanoma; choriocarcinoma; seminoma and mesothelioma (Funai et al., 1981; Mori et al., 1987; Kadowaki and Ikoma, 1990; Saiki et al., 1992; Kawai et al., 1993; Mochimatsu et al., 1993; Akiyama et al., 1995; Hando et al., 1995; Yamauchi et al., 1995). On the other hand, the reported metastatic sites in the head and neck from HCC are the orbit, paranasal sinus, gingivobuccal mucosa, palatine tonsil and lingual tonsil (Saiki et al., 1992; Kawai et al., 1993).

Why are tonsillar metastases rare? It has been hypothesized that translymphangial metastasis is rare to occur because the tonsil has no afferent lymph duct (Draizin et al., 1978). The tonsil has a high ability to eliminate cancer cells by immunosurveillance (Funai et al., 1981), so tonsillar metastases are rarely searched for at general postmortem examinations (Tanaka et al., 1981).

The most common sites for extrahepatic metastases from HCC are the lung, peritoneum, bone, intracranial organs and adrenal gland. The patient's tumor must have metastasized through the tonsillar hilus because HCC usually causes transvascular metastasis.

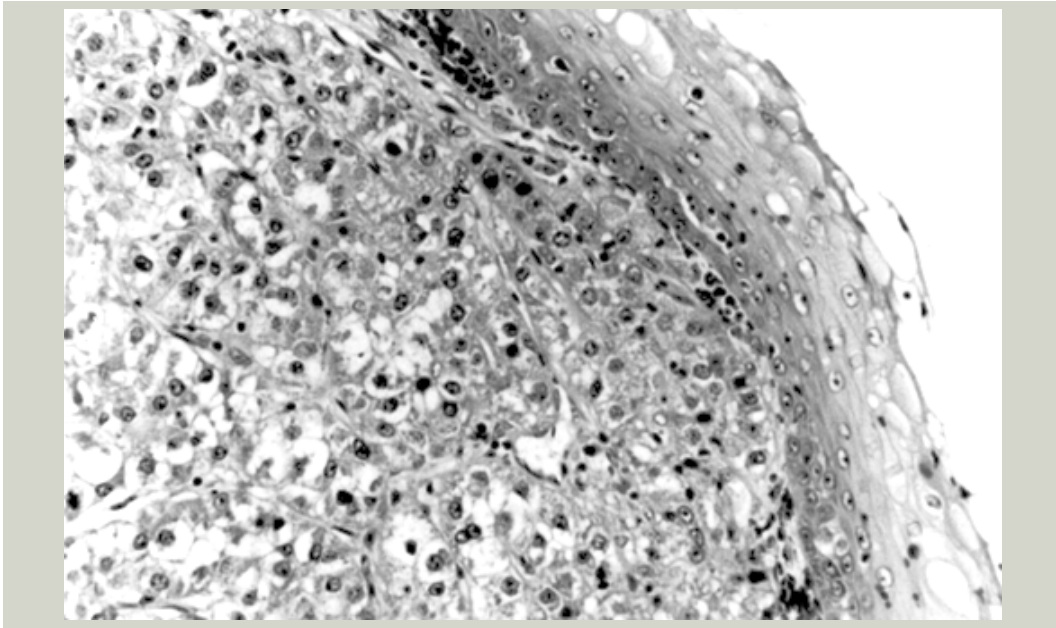


Fig. 3. Histological findings of the tumor (hematoxylin and eosin staining, $\times 100$). The surface tissue is the stratified flattened epithelium, but the inside tissue is of the hepatocellular carcinoma with sinusoidal patterned cells. Immunohistochemical staining of alpha-fetoprotein was negative, but that of carcinoembryonic antigen was positive.

In patients with tonsillar metastases, the lesions are mostly unilateral, but several papers reported bilateral occurrences (Draizin et al., 1978; Kadowaki and Ikoma, 1990).

The metastases usually appear within 1 year after the occurrence of the primary tumor. In some uncommon cases, however, lesions occurring before the existence of a primary tumor has been noted, which allows for the definite diagnosis of the primary tumor (Fernández Aceñero et al., 1996). Similarly, both the present patient and the patient in San Carlos University Hospital (Llanes et al., 1996) were diagnosed as HCC due on the metastasis to the unilateral palatine tonsil.

The common symptoms of metastatic tumors of the tonsil are pharyngeal discomfort, pain and bleeding. Because the symptoms are weak in most cases, the metastases are generally found in the advanced stage. Furthermore, they are usually a late event in the progression of HCC, so that prognosis is generally poor once its metastatic lesion is found. Kanazawa and Sato (1989) explained that the mean surviv-

al rate after the appearance of oral metastases was 21 weeks, ranging from 2 weeks to 2 years. The patient in San Carlos University Hospital died 8 months after the diagnosis of tonsillar metastasis.

Major treatment is resection of the tumor by palatine tonsillectomy. The operation is very useful for prevention of such complications as pharyngeal pain, dyspnea, dysphagia and severe bleeding (Hando et al., 1995; Yamauchi et

Table 1. The primary sites for tonsillar metastases reported in Japan

Primary site	Number of patients
Pulmonary cancer	24
Gastric cancer	8
Liver cancer	8*
Colon cancer	3
Malignant melanoma	3
Choriocarcinoma	3
Renal cancer	2
Breast cancer	2
Others	4

*Including the present patient.

al., 1995). And we should always respect the patients' quality of life during treatment because of the poor prognosis.

References

- 1 Akiyama Y, Yagi M, Murakami M, Yasuda N, Hisa Y. Tonsillar metastasis from small cell lung carcinoma: report of a case. *Nisseki Igaku* 1995; 47:247–250 (in Japanese with English abstract).
- 2 Brownson RJ, Jaques WE, LaMonte SE, Zollinger WK. Hypernephroma metastatic to the palatine tonsils. *Ann Otol Rhinol Laryngol* 1979;88:235–240.
- 3 Draizin D, Matucci K, Royhfeld S. Bilateral metastatic tonsillar disease due to renal cell carcinoma. *Ear Nose Throat J* 1978;57:14–18.
- 4 Fernández Aceñero MJ, Pascual Martín A, Martín Rodilla C, Blanco González J, Ispizua Uribarri JJ, Sanz Esponera J. Tonsillar metastases: report on two cases and review of literature. *Gen Diagn Pathol* 1996;141:269–272.
- 5 Funai H, et al. Tonsillar metastasis of hepatoma: report of a case. *Jibiinkoka* 1981;53:421–423 (in Japanese with English abstract).
- 6 Hando S, Sato Y, Hasegawa S, Nishiwaki C. Three cases of metastatic tonsillar tumor. *Kenritsu Gan Senta Niigata Byoin Ishi* 1995;34: 61–64 (in Japanese with English abstract).
- 7 Kadowaki K, Ikoma H. Metastatic carcinoma of the bilateral tonsils owing to gastric cancer: a case report. *Jibi To Rinsho* 1990;36:1144–1146 (in Japanese with English abstract).
- 8 Kanazawa H, Sato K. Gingival metastasis from primary hepatocellular carcinoma: report of a case and review of literature. *J Oral Maxillofac Surg* 1989;47:987–990.
- 9 Kawai A, Orita Y, Yamamoto H, Akisada T, Yamakawa J, Yoshihiro T. Metastasis from pancreatic carcinoma to palatine and lingual tonsil: a case report. *Jibiinkoka Rinsho* 1993;86:839–845 (in Japanese with English abstract).
- 10 Llanes F, Sanz-Ortega J, Suarez B, Sanz-Esponera J. Hepatocellular carcinomas diagnosed following metastasis to the oral cavity. Report of 2 cases. *J Periodontol* 1996;67:717–719.
- 11 Mochimatsu I, Tsukada M, Furukawa S, Sawaki S. Tumors metastasizing to the head and neck: a report of seven cases. *J Laryngol Otol* 1993;107: 1171–1173.
- 12 Mori S, Sakurai K, Kuroyanagi H, Kishimoto A, Takatsu A, Iwata S. Tonsillar metastasis from lung cancer: a case report. *Jibiinkoka Rinsho* 1987;80:1261–1265 (in Japanese with English abstract).
- 13 Saiki T, et al. Metastatic hepatocellular carcinoma of tonsil: report of a case. *Jibiinkoka Tokeibu Geka* 1992;64:747–751 (in Japanese with English abstract).
- 14 Tanaka N, Toya M, Koyanagi Y. Tonsillar metastasis from carcinoma of the stomach: report of a case. *Jibi To Rinsho* 1981;27:811–814 (in Japanese with English abstract).
- 15 Yamauchi H, et al. Tonsillar metastasis from gastric cancer: a case report. *Jibiinkoka Tokeibu Geka* 1995;67:650–654 (in Japanese with English abstract).

(Received August 20, Accepted September 27, 1999)